

Antibiotic Cement–Coated Nail for the Treatment of Infected Nonunions and Segmental Bone Defects

Raghuram Thonse, MS Orth, DNB Orth, FRCS Ed, FRCS, Glasg, and Janet D. Conway, MD

Introduction and Methods 1 and 2

Introduction

Stabilizing a nonunion in the presence of a bone infection is a challenge. Traditional treatment has used antibiotic beads to treat the infection followed by a second procedure to provide bone stability.^{1,2,3,4} The nonunion can be bridged with external fixation to provide stability; however, many patients are not ideal candidates for external fixation.

Antibiotic cement-coated intramedullary rods are able to treat the infection with high doses of local antibiotics while providing bone stability.⁵ The technique allows for immediate weight bearing and prevents complications that might occur during external fixation, such as pin tract infections and joint stiffness. This novel approach to infected nonunions was developed to minimize the number of additional surgical procedures for infection control and bone union. We present our series of 52 cases of antibiotic cement-coated intramedullary rods for treatment of infected nonunions and segmental bone defects.

Methods

Two methods have been used to create the antibiotic-coated intramedullary rods. Initially, rods were made using a mold technique, which is called Method 1. The second generation of intramedullary rods was made with Method 2 and uses silicone tubing.

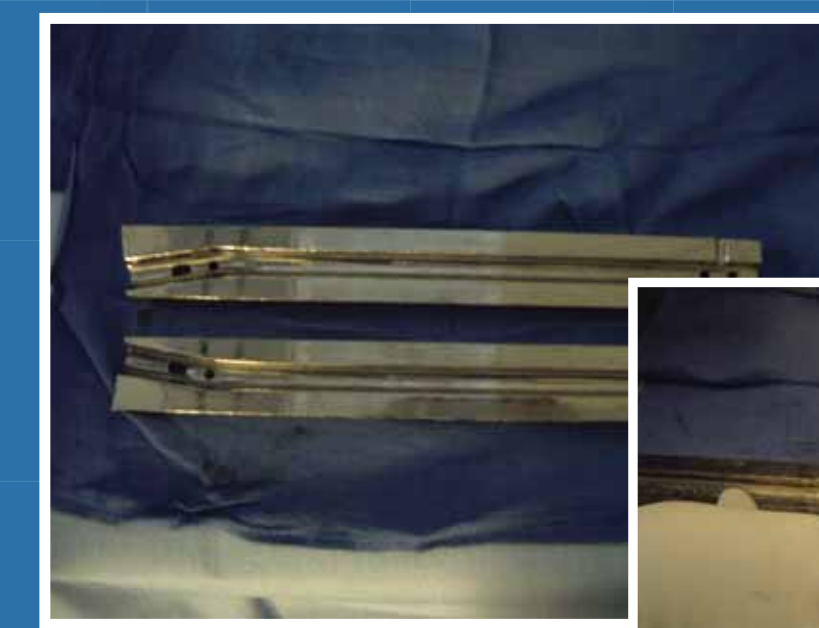Intraoperative rod preparation time for Method 2 is approximately 10 minutes, which is substantially less than the time it took to prepare a rod using Method 1 (1 hour). Additional advantages of Method 2 include the uniformity and improved reliability of the coating and that no insertional debondings have occurred.

All rods were made with the same antibiotic recipe of 3.6 g of tobramycin and 1 g of vancomycin per 40-g package of cement. If a patient had a vancomycin allergy (two patients), only tobramycin was used. Extra monomer was necessary for mixing the large quantity of antibiotics with the cement.

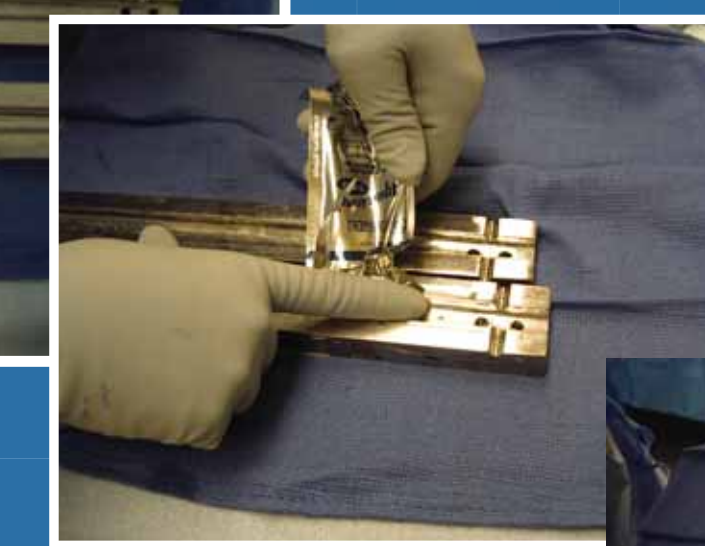

Method 1

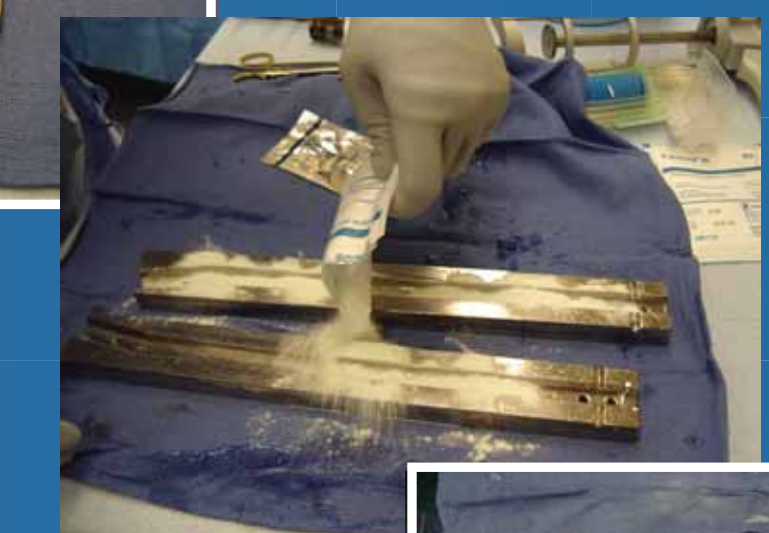1. Coat mold with sterile ultrasound gel.



2. Coat mold with sterile ultrasound gel.



3. Sprinkle dry cement powder over ultrasound gel.



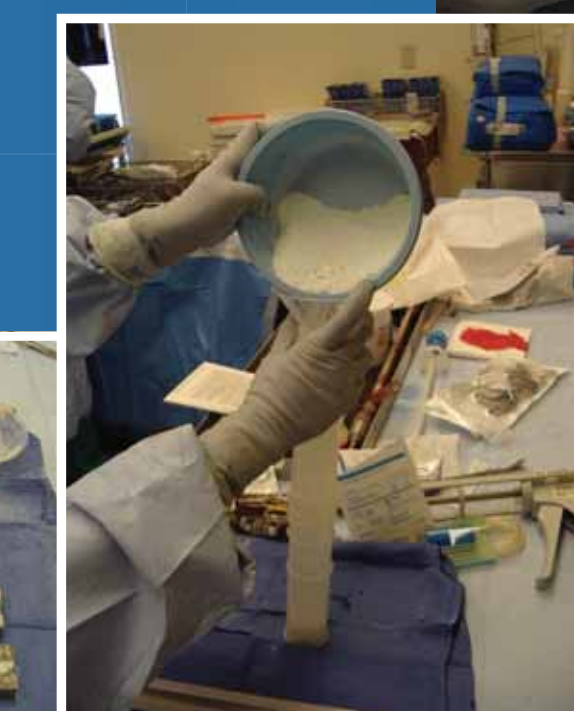4. Shake off excess powder.



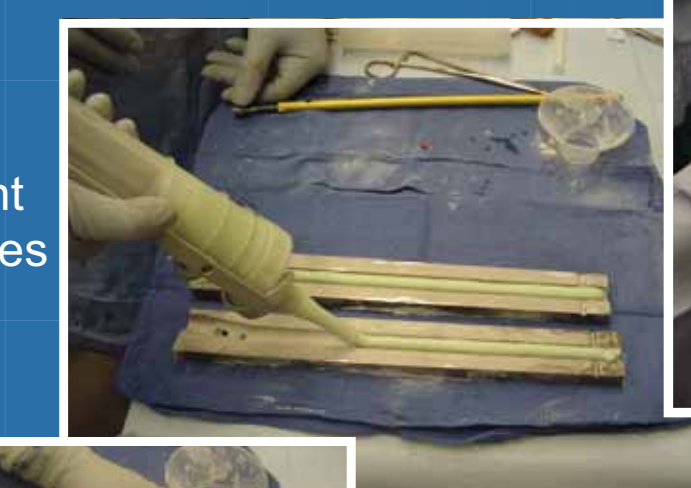5. Mix all powdered antibiotics with cement.



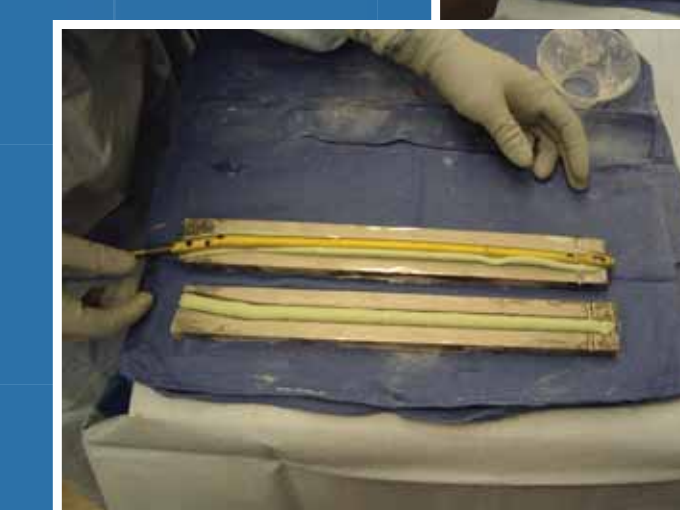6. Add to cement gun with monomer and mix cement until homogeneous.



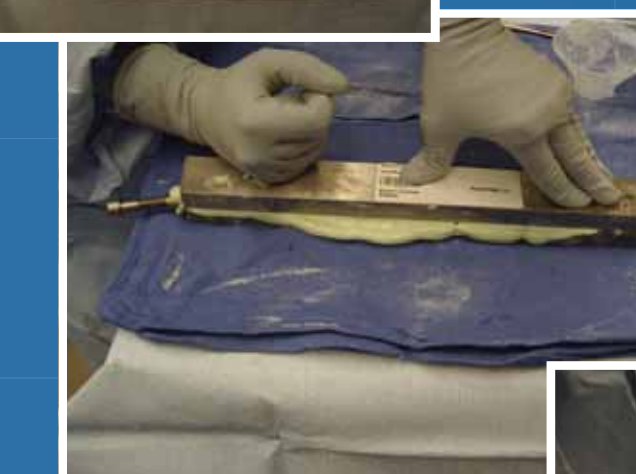7. Using the cement gun, place cement into both sides of the mold.



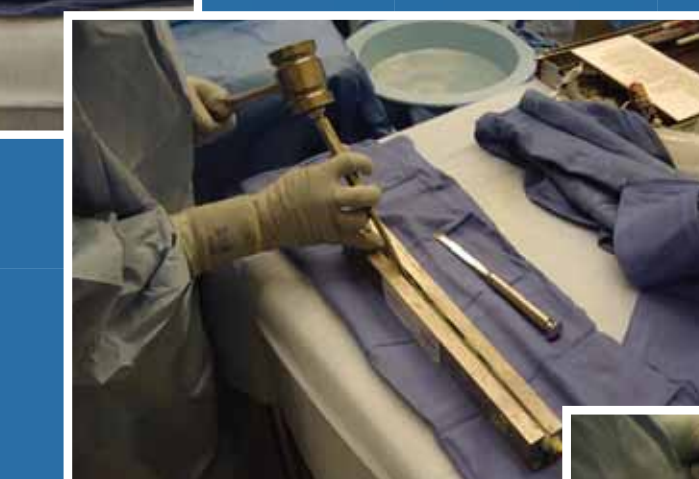8. Then place the rod into one side.



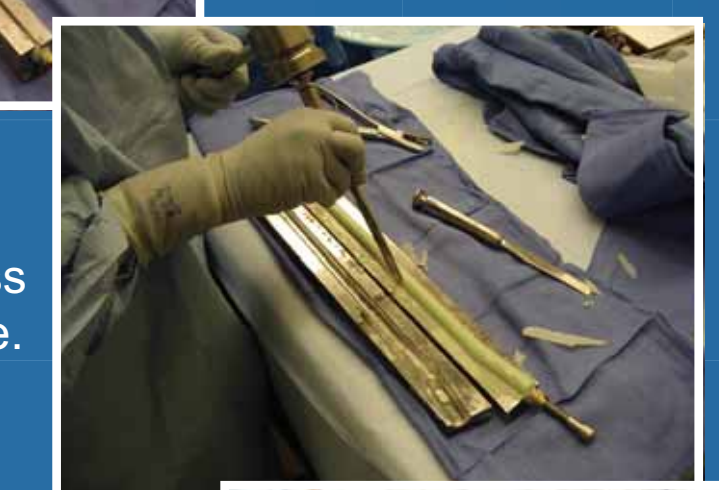9. Close the mold carefully and make sure the rod is still centered in the mold. Keep the insertion threads of the proximal rod free of cement.



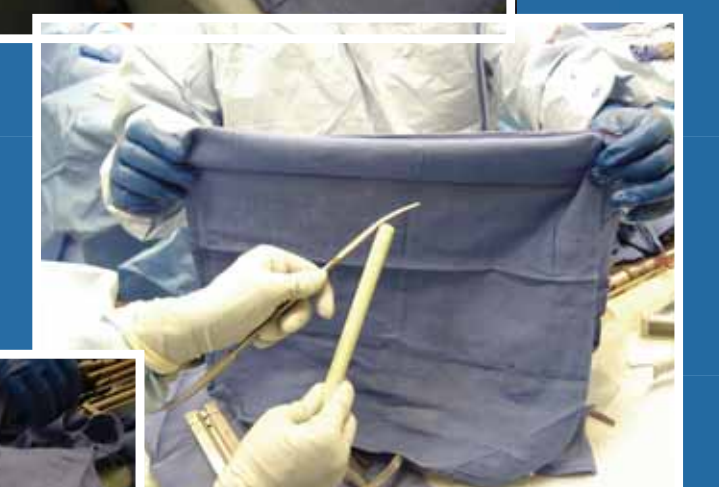10. Carefully open mold.



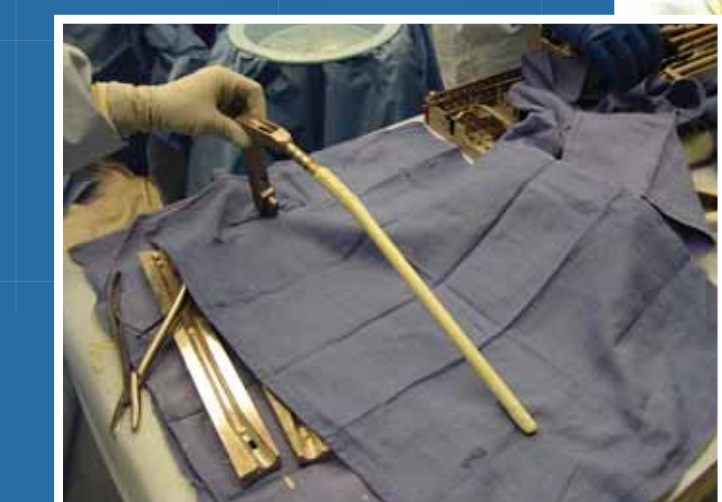11. Begin to remove excess cement with osteotome.



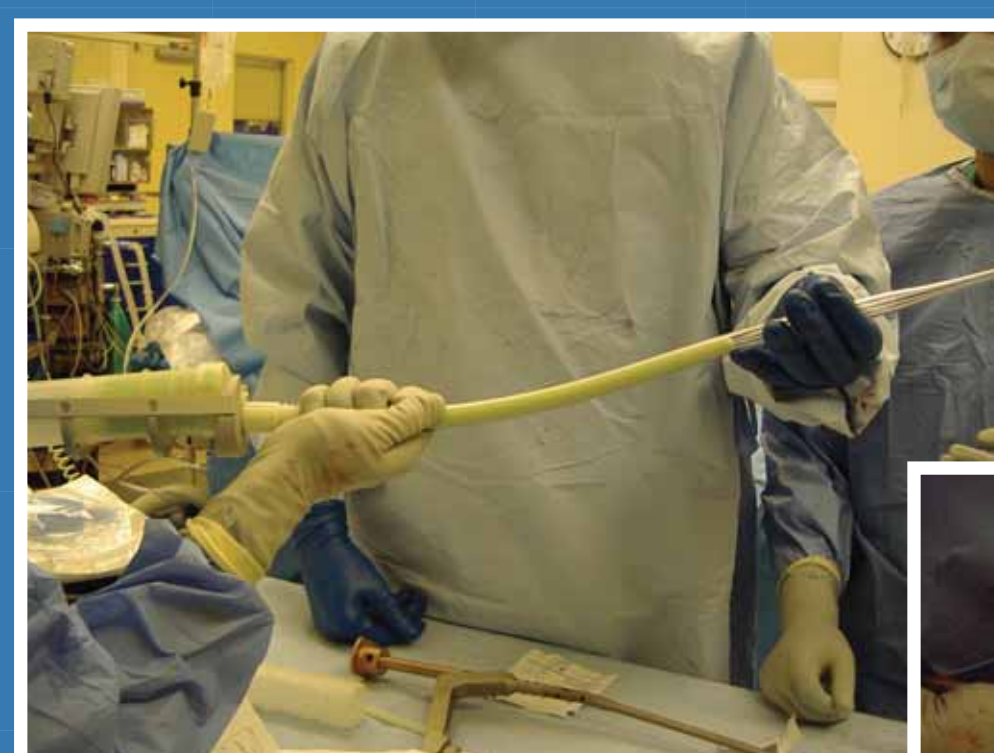12. File tip to bullet shape for ease of insertion.



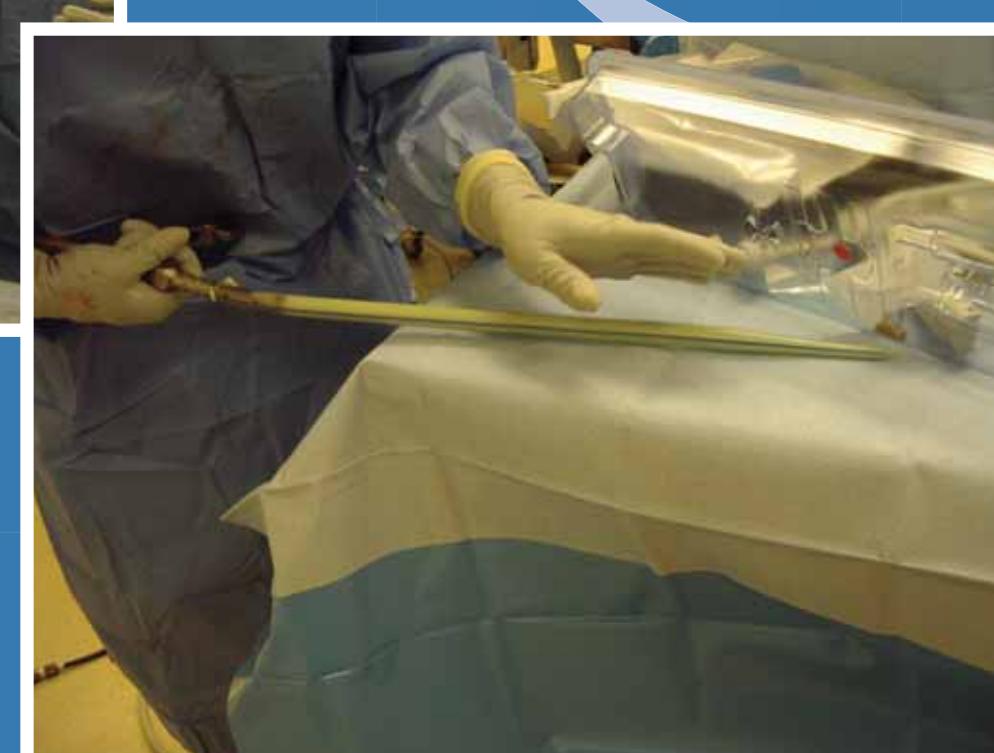13. The rod is ready to be inserted.



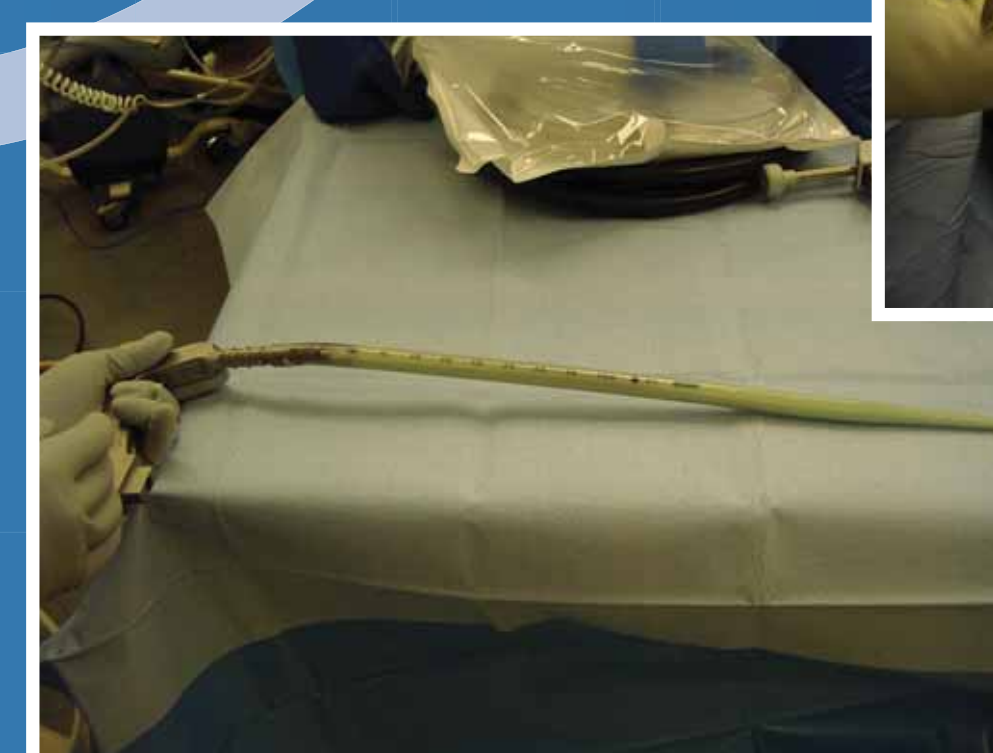Method 2



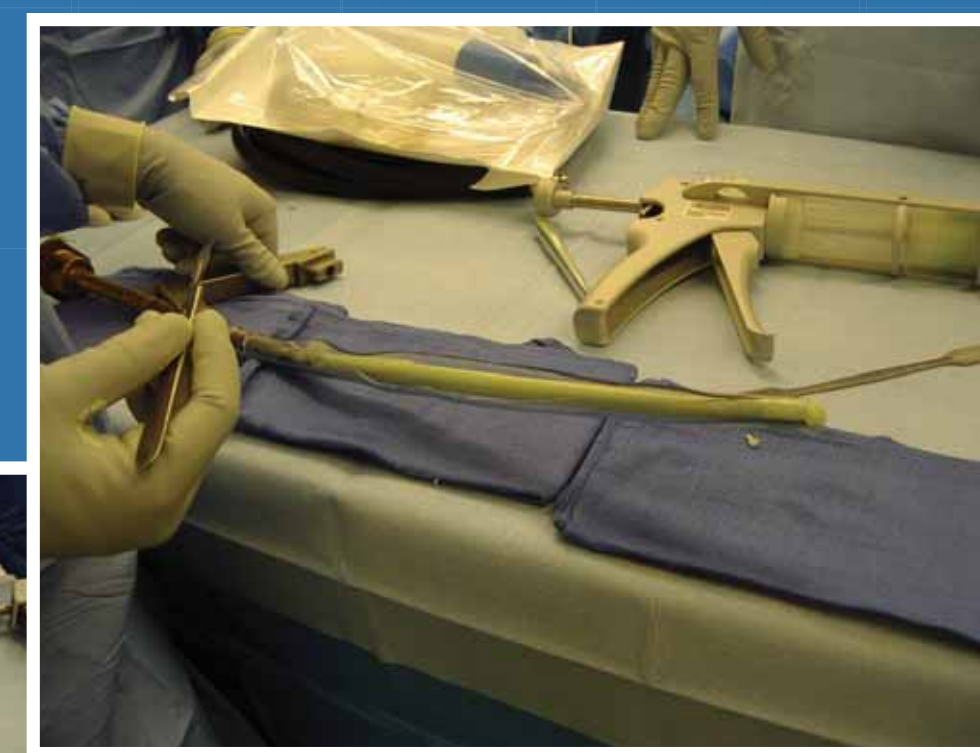1. After mixing cement as in Method 1, use the cement gun to insert cement into the 12.5-mm inner diameter silicone tubing.



2. Carefully insert the rod into the silicone tubing. Inspect rod and roll carefully in the tubing to ensure uniform coating.



3. Cut and peel off silicone tubing.



4. Rod is ready to be inserted.

Results

Demographics

Total

52 cases (12 females, 40 males)
 Average age: 46.2 years (range, 16–86 years)
 Cierny-Mader host status⁶: 38B, 14A
 Average length of follow-up:
 15.6 months (range, 1–60 months)

Method 1: Mold

32 cases (23 males, 9 females)
 Average age: 46.5 years (range, 16–86 years)
 Cierny-Mader Host Status: 24B, 8A
 Average length of follow-up:
 22.5 months (range, 2–60 months)

Method 2: Silicone Tubing

20 cases (17 males, 3 females)
 Average age: 45.7 years (range, 19–80 years)
 Cierny-Mader host status: 14B, 6A
 Average length of follow-up:
 4.5 months (range, 1–12 months)

Diagnosis

Total:

17 segmental bone defects after débridement
 34 infected nonunions or arthrodeses
 1 acute fracture after an external fixator

Method 1: Mold

17 infected nonunions
 15 segmental defects (Average size of defect, 8.63 cm; range, 1–30 cm)

Method 2: Silicone Tubing

17 infected nonunions
 2 segmental defects (6 cm and 1.5 cm)
 1 acute fracture

Cultured Organisms

Total	M1: Mold	M2: Silicone Tubing
Multiple organisms	11	4
MRSA	17	13
<i>Pseudomonas</i>	1	2
<i>Enterobacter</i>	4	1
<i>E. coli</i>	3	0
<i>Serratia marcescens</i>	3	0
<i>Acinetobacter</i>	1	2
Strep B	2	0
enterococcus	2	0
Coagulase-negative <i>Staphylococcus</i>	2	3
<i>S aureus</i>	3	0
<i>S viridans</i>	1	0
<i>Morganella</i>	1	0
<i>S agalactiae</i>	1	0
<i>Corynebacterium</i>	2	0
<i>Micrococcus</i>	1	0
<i>Proteus</i>	0	2
<i>Citrobacter</i>	1	0
<i>Klebsiella</i>	0	1

MRSA, Methicillin-resistant *Staphylococcus aureus*. The most common outlined organism in both methods was MRSA.

Type of Rod	M1: Mold	M2: Silicone Tubing	Total
Hindfoot fusion	7	7	16
Tibial	7	7	11
Femoral antegrade	7	7	10
Knee arthrodesis	9	9	12
Femoral retrograde	2	2	3

Additional Procedures for Infection

	M1: Mold	M2: Silicone Tubing	Total
Rod removal	3	0	3
Débridement	2	1	3
Femoral antegrade	5	2	7
AKA	2	0	2
Total	12	3	15

AKA, Above-knee amputation.

Additional Procedures for Union: Bone Graft With or Without Additional Fixation

	Total	Union	Percentage
Total	10	10/49	20.0%
M1: Mold	6	6/29	20.7%
M2: Silicone Tubing	4	4/20	20.0%

Results

Total	
Bone union achieved	83.7% of patients (41/49)* 89.8% including stable nonunions (44/49)
Infections eradicated	84.6% of patients (44/52)
Patients with additional procedures for infection or nonunion	26.9% of patients (14/52)
Patients requiring only index antibiotic-coated rod	73.1% of patients (38/52)

M1: Mold	
Bone union achieved	86.2% of patients 25/29** 93.1% including stable nonunions (27/29)
Infections eradicated	78.1% of patients (25/32)
Patients with additional procedures for infection or nonunion	37.5% of patients (12/32)
Patients requiring only index antibiotic-coated rod	62.5% of patients (20/32)

M2: Silicone Tubing	
Bone union achieved	95.0% of patients (19/20)**
Infections eradicated	80.0% of patients (16/20)
Patients with additional procedures for infection or nonunion	15.0% of patients (3/20)
Patients requiring only index antibiotic coated rod	85.0% of patients (17/20)

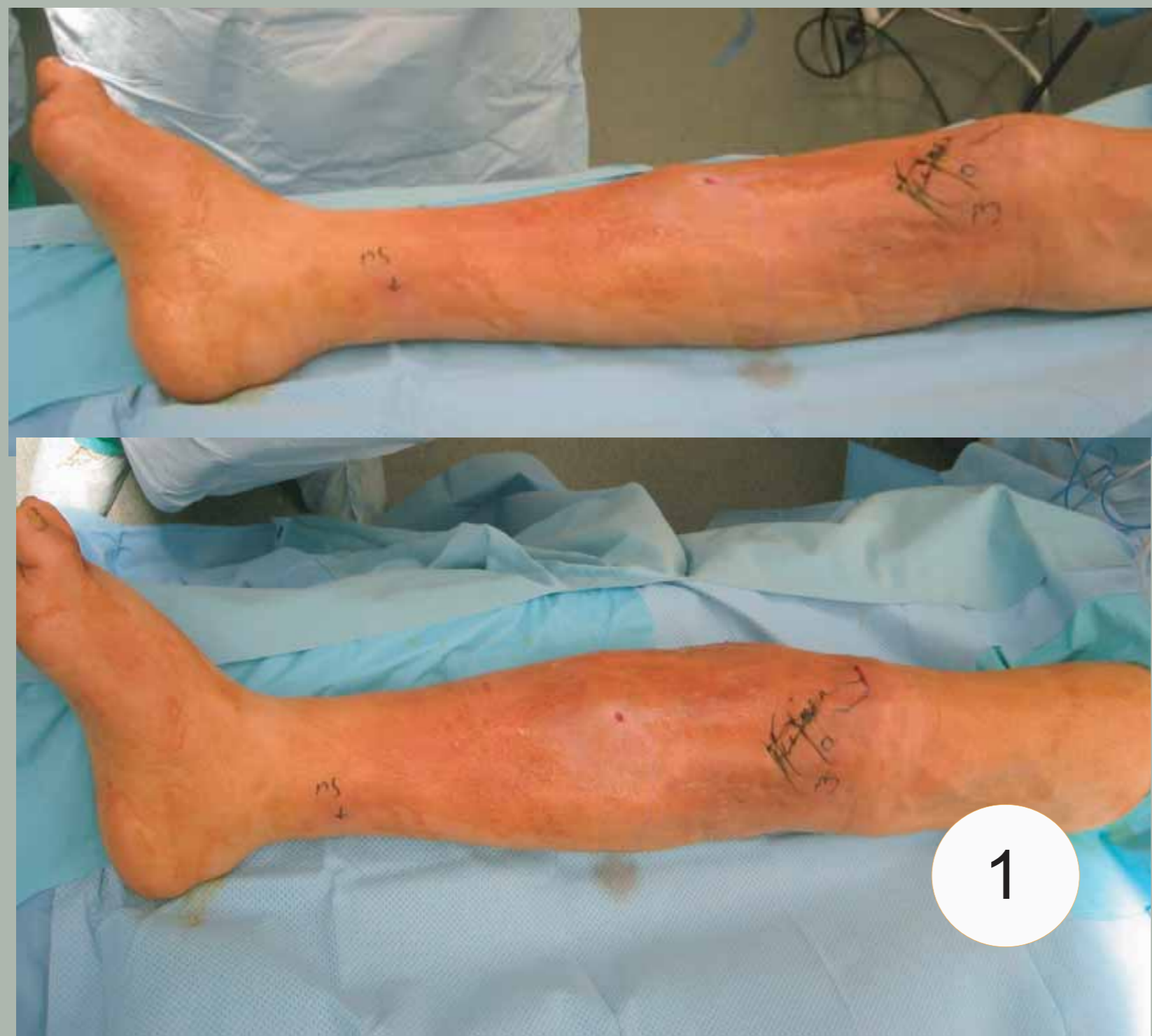Results

The antibiotic cement-coated intramedullary rod has a 73.1% success rate of treating the difficult problem of infected nonunion with one surgical procedure. Twenty-six percent of patients underwent an average of one additional procedure to treat infection or nonunion. Only two patients in this study underwent amputation; the overall limb salvage rate was 96%. Average follow-up for Method 1 and Method 2 was 22.5 months and 4.5 months, respectively. The majority of patients in the study had MRSA, and a large number of patients were infected with multiple organisms. Method 2 had a larger number of patients with additional procedures secondary to their larger number of segmental bone defects as well as complicated infections with multiple organisms.

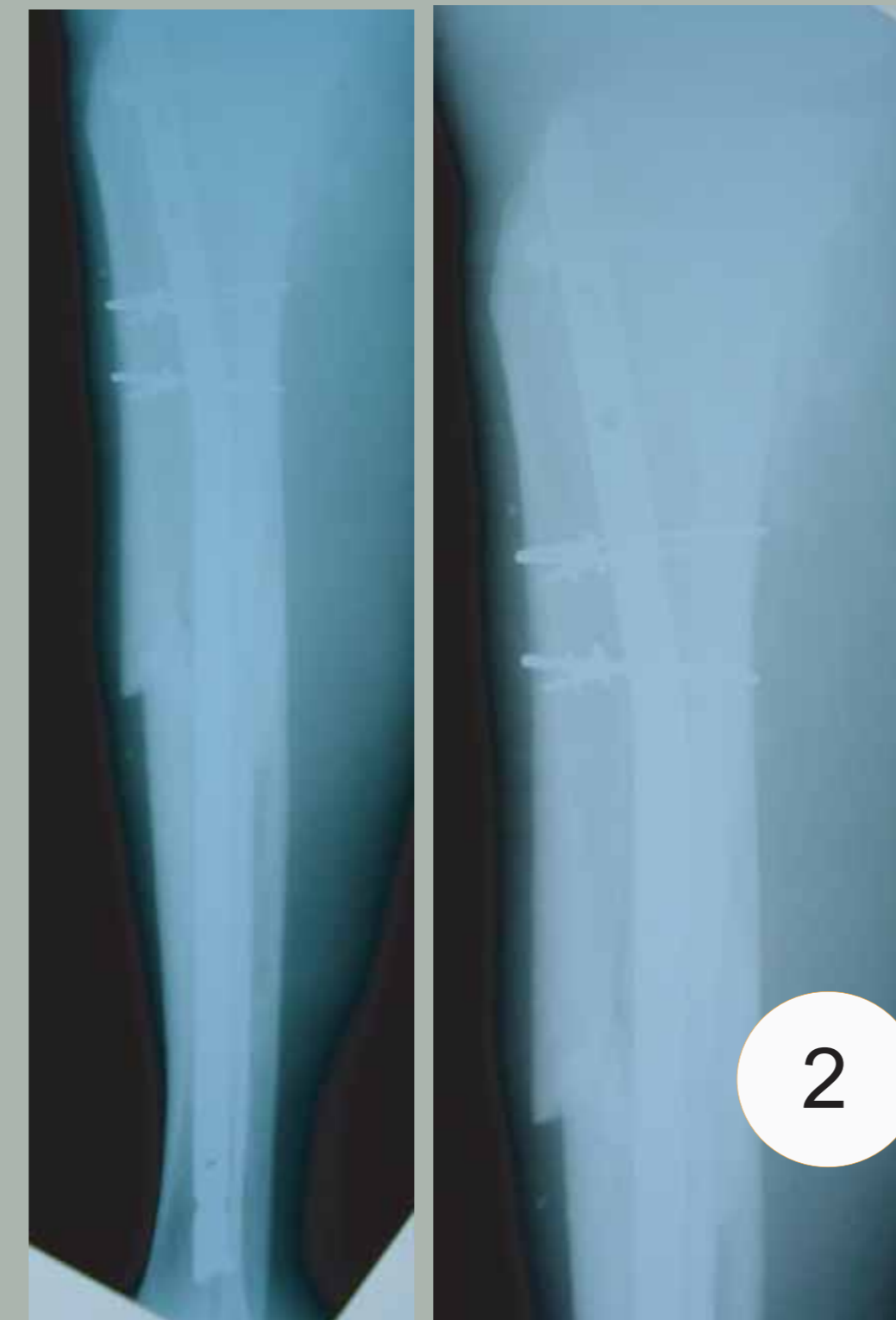Method 2 using silicone tubing had a smaller number of rod/coating related complications and is now our preferred method (see table). The most common intramedullary rod used was a hindfoot fusion rod, and the next most common rod was the knee fusion rod.

Cases 1 and 2

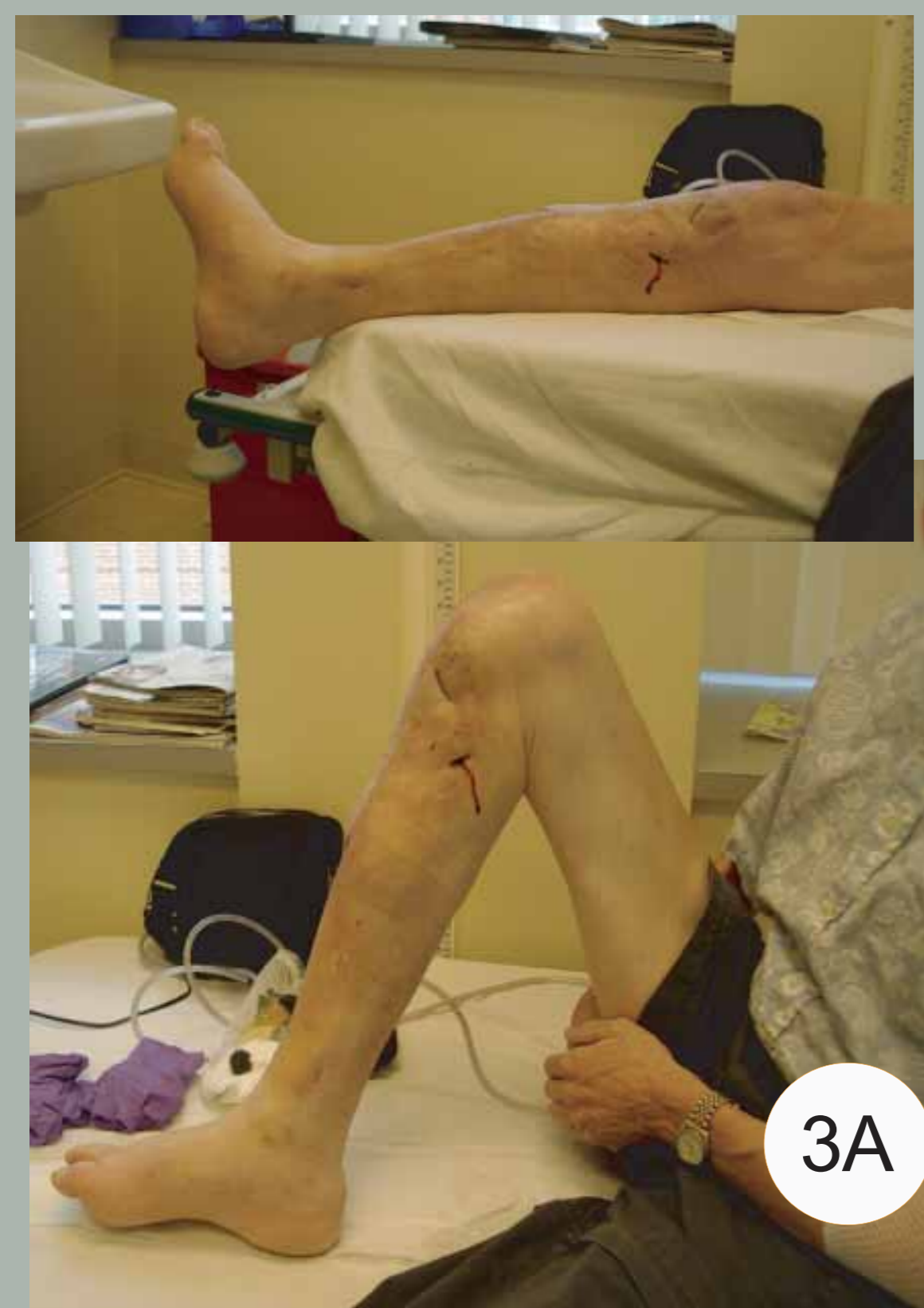
Case 1



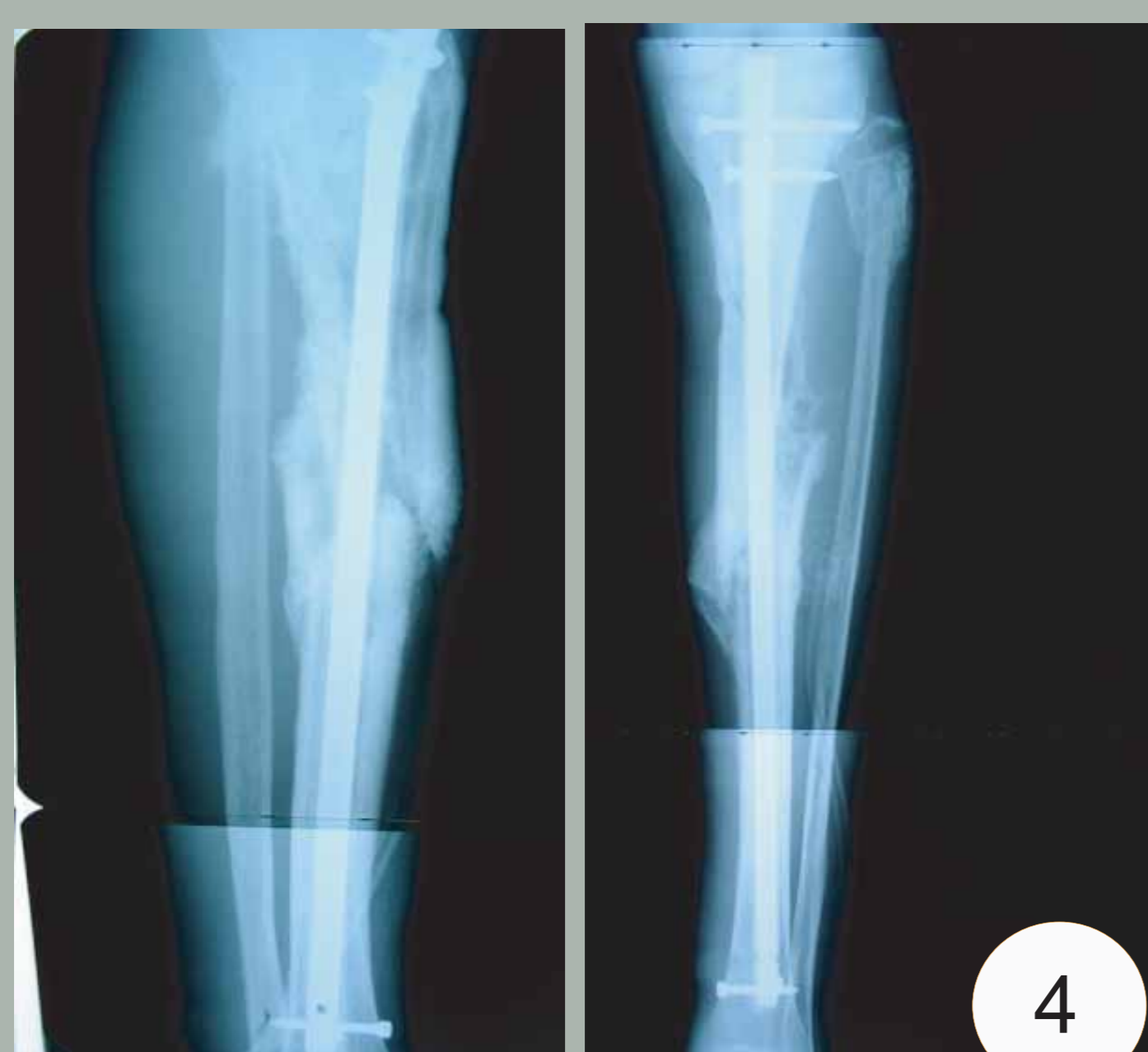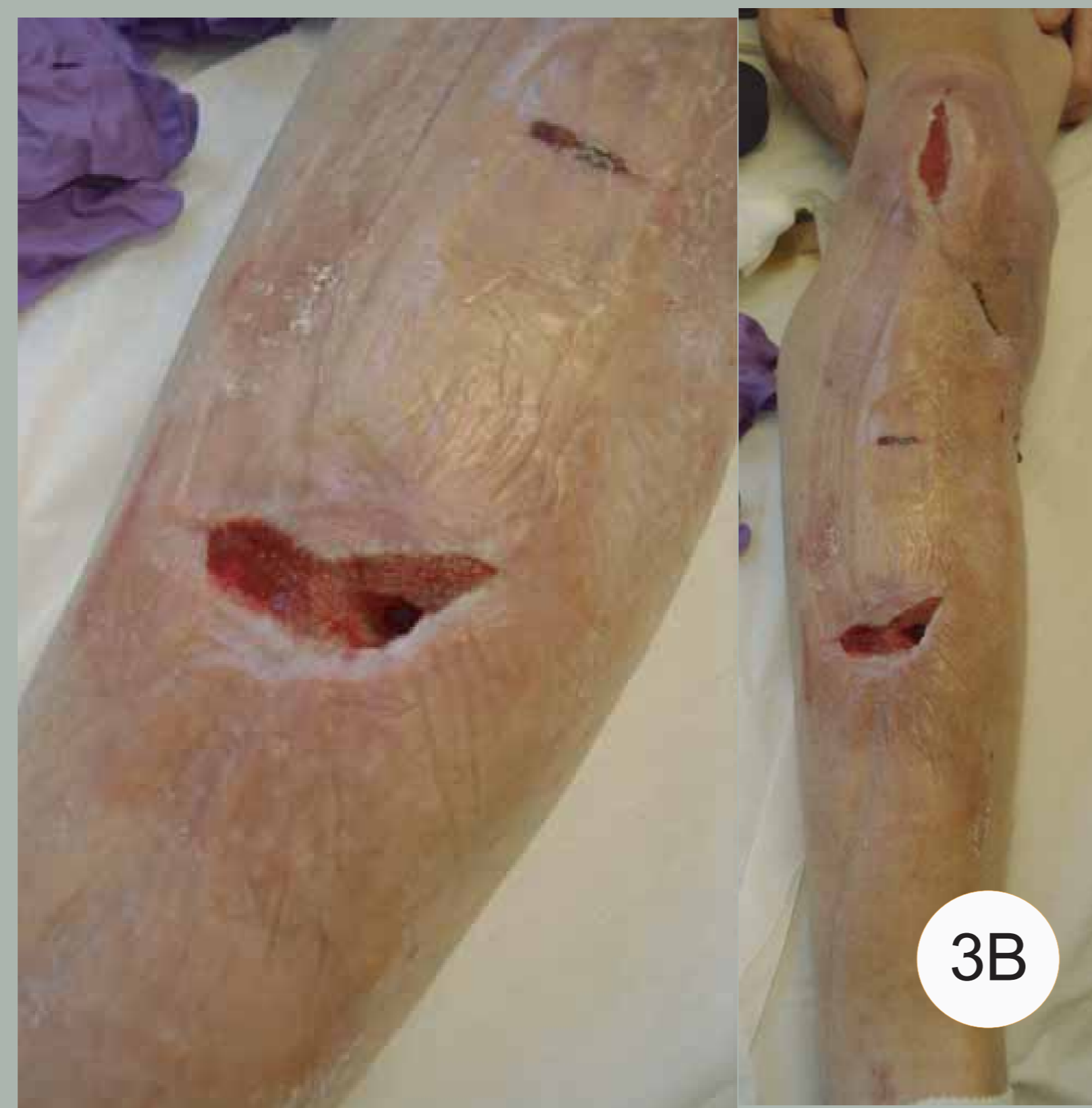Preoperative photo: 58-year-old male with diabetes and a segmental tibial shaft fracture treated with IM rod. Photo obtained 3 weeks after initial surgery. Patient has cellulitis and deep infection.



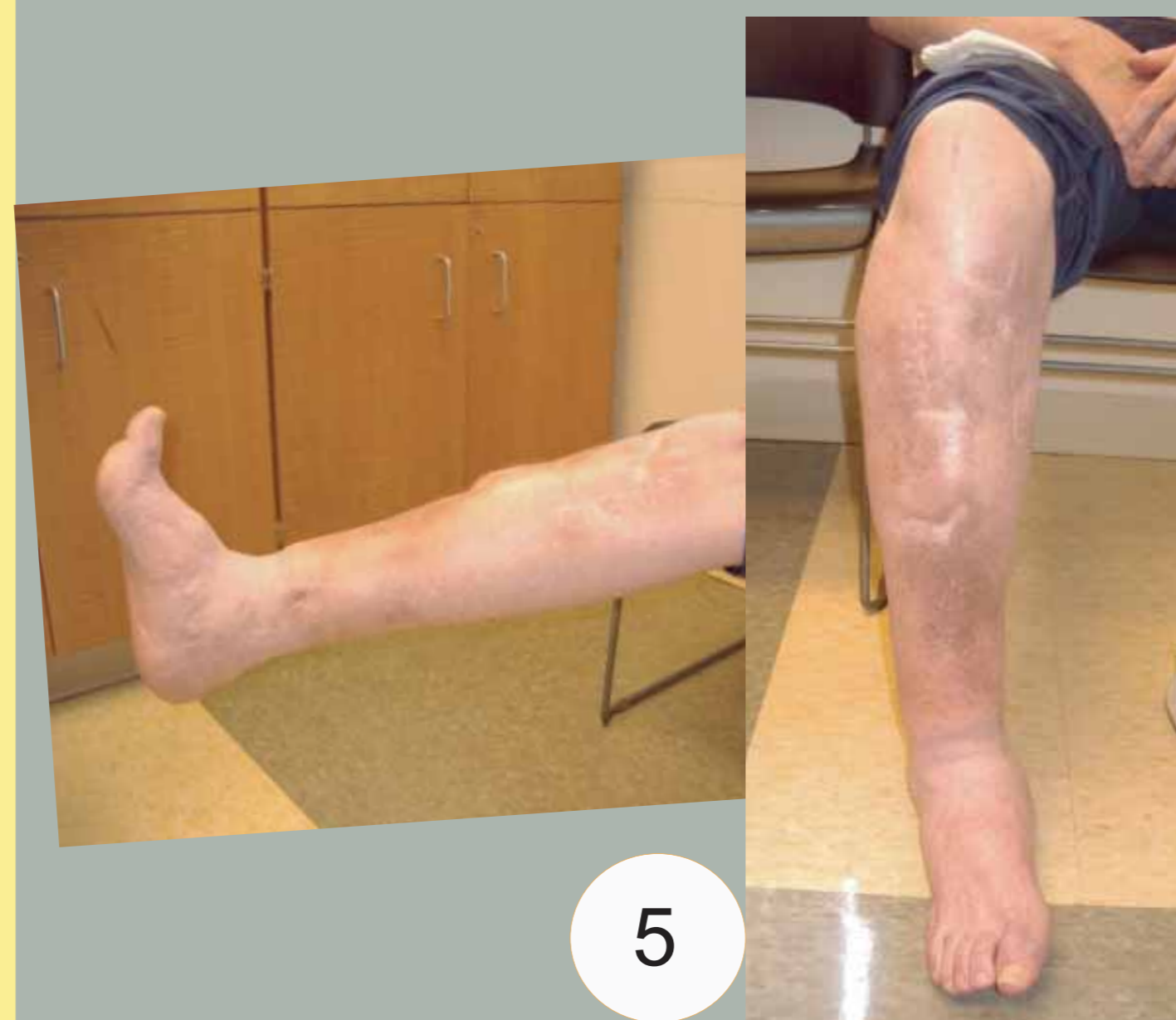Preoperative radiographs.



Two-week postoperative visit.

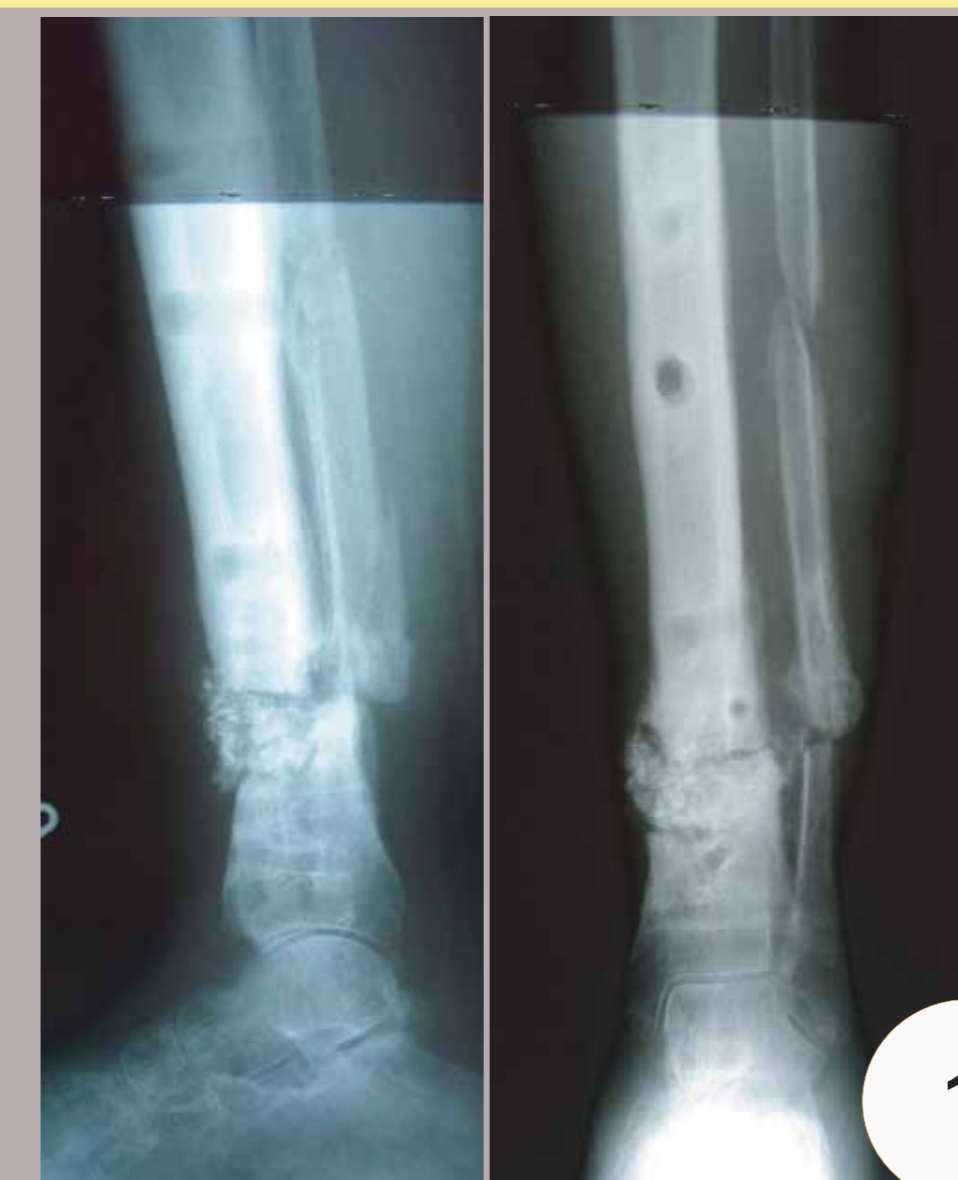

Three-months postoperative radiographs.

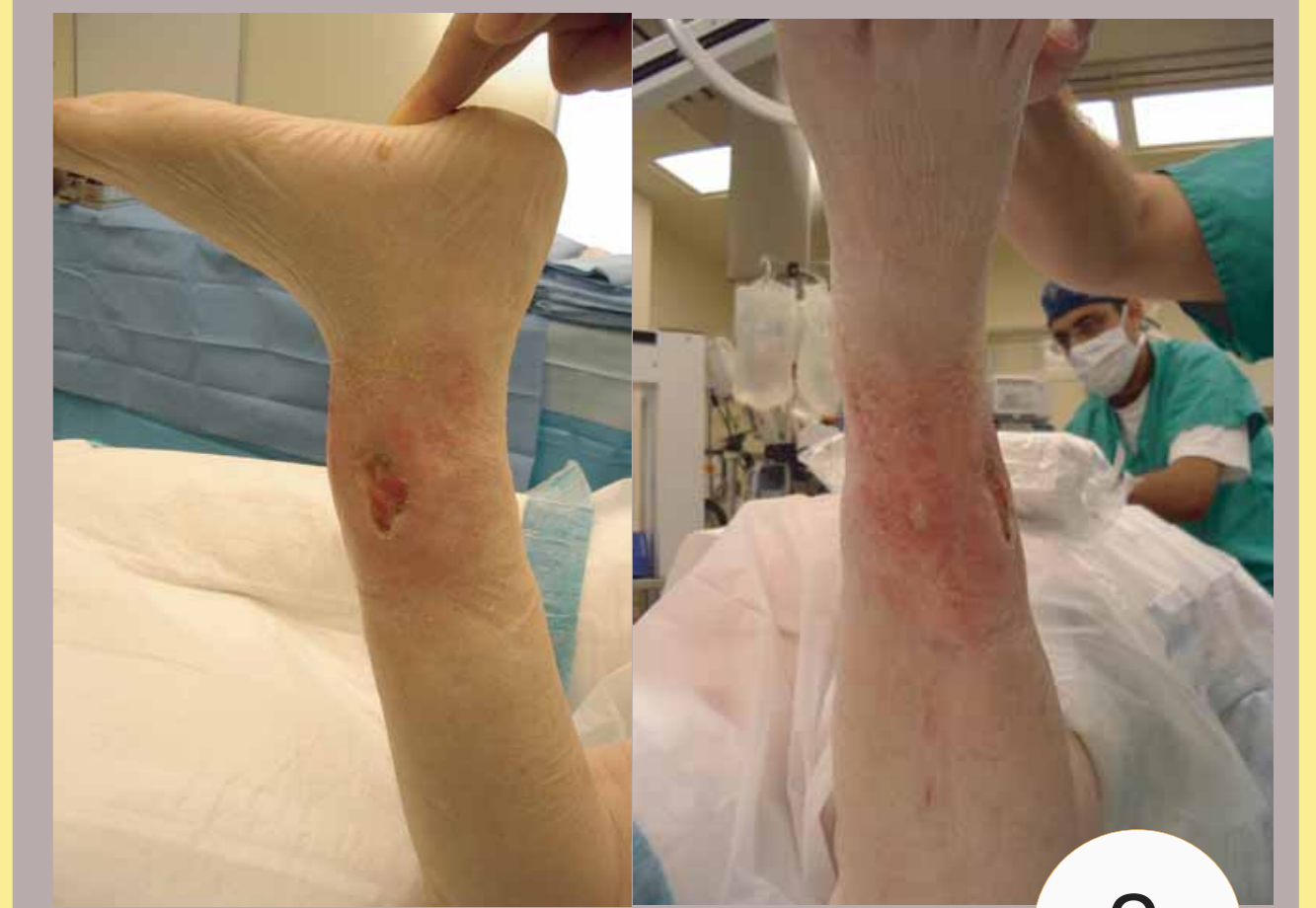

Two-year follow-up. Complete healing was achieved and there was no sign of infection.

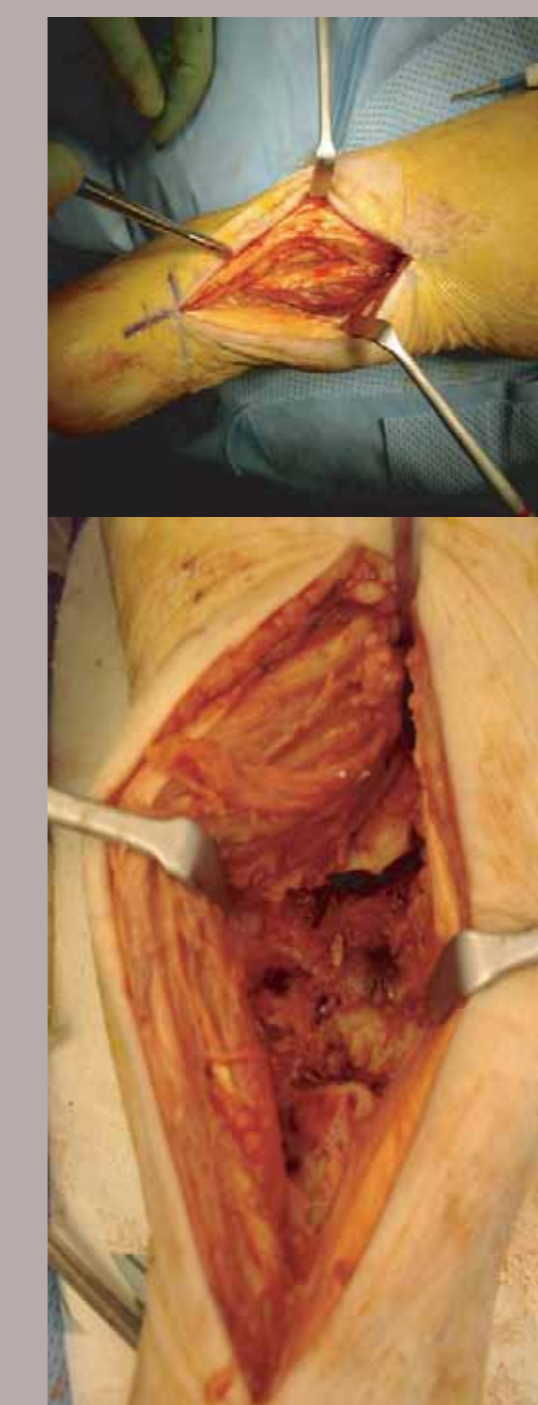Case 2



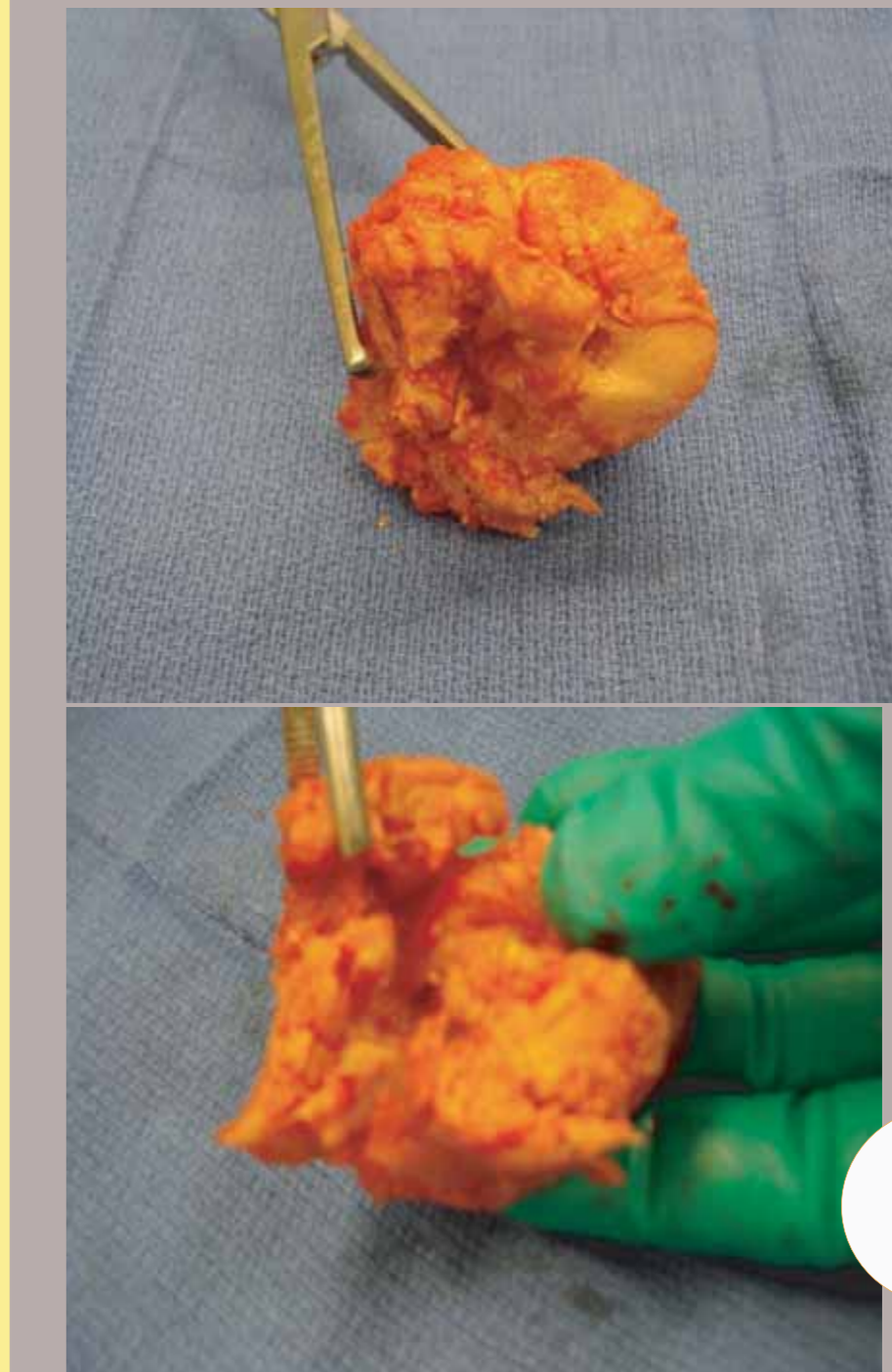
Preoperative radiographs: 60-year-old female with infected distal tibial nonunion, diabetes, and one-vessel leg. Failed previous Alizaron treatment.



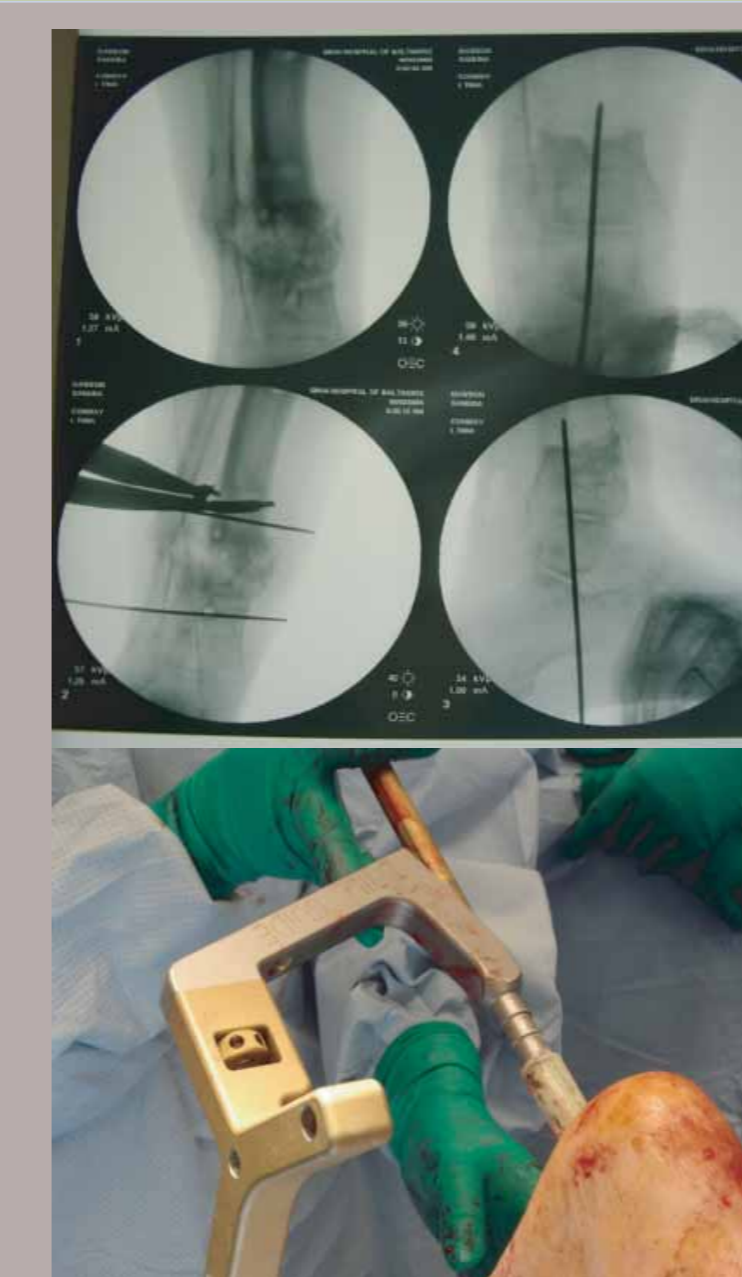
Preoperative clinical photo shows poor anterolateral soft envelope.



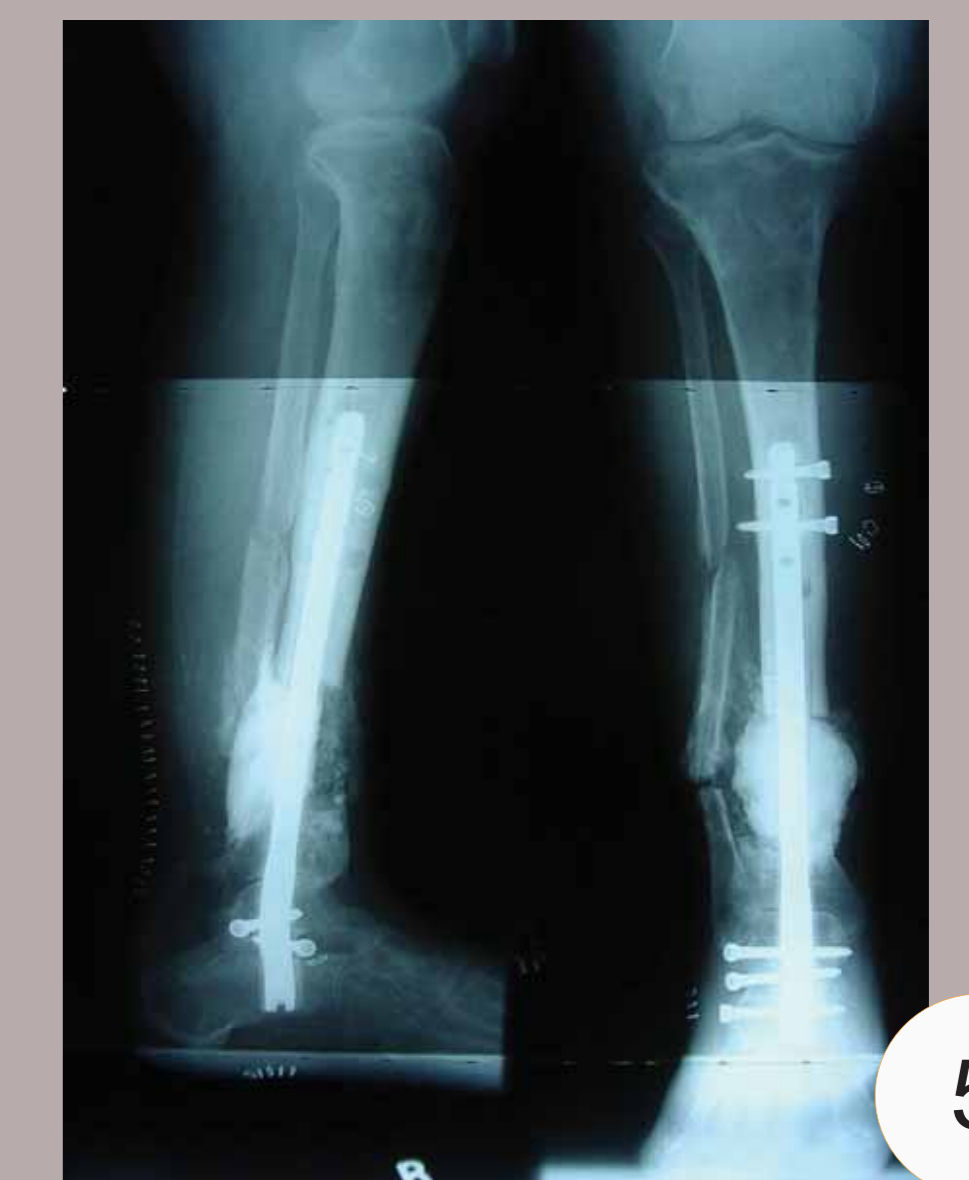Trans-Achilles approach with resected nonunion.



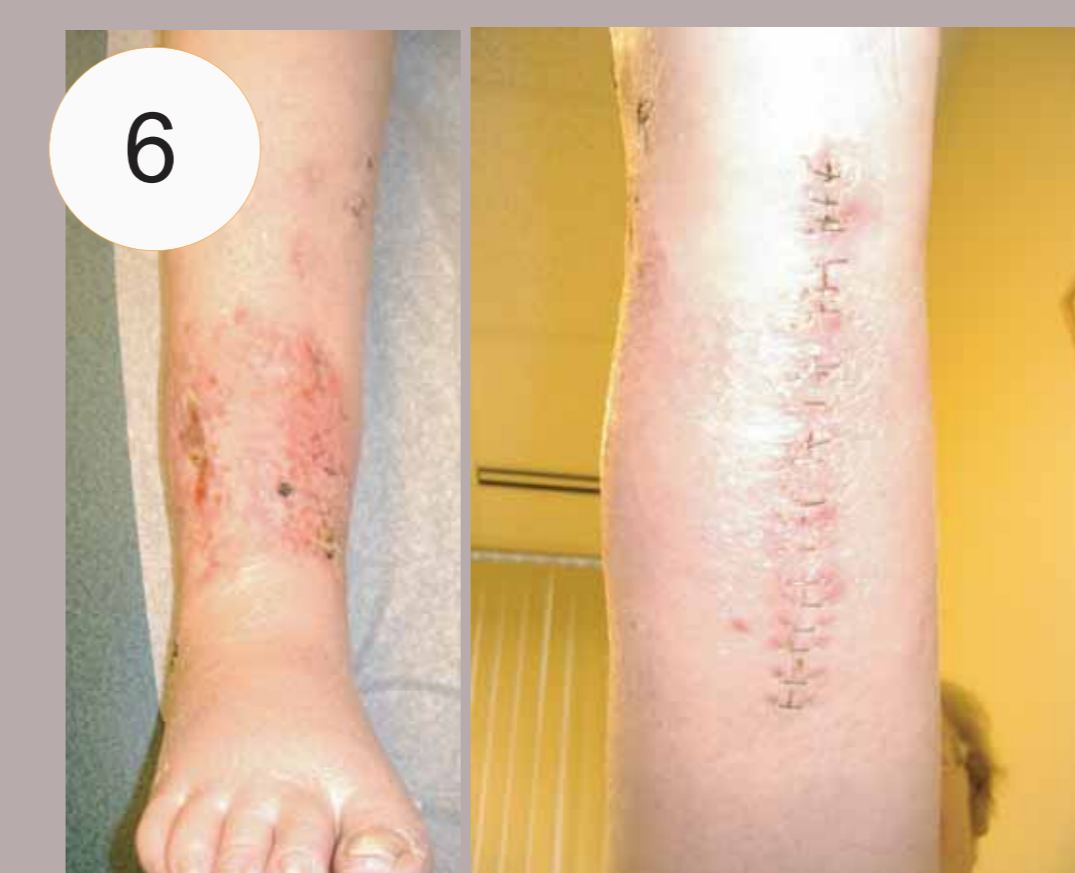Resected nonunion.



Intraoperative fluoroscopic images and photo of rod insertion.



Six-month postoperative radiographs.

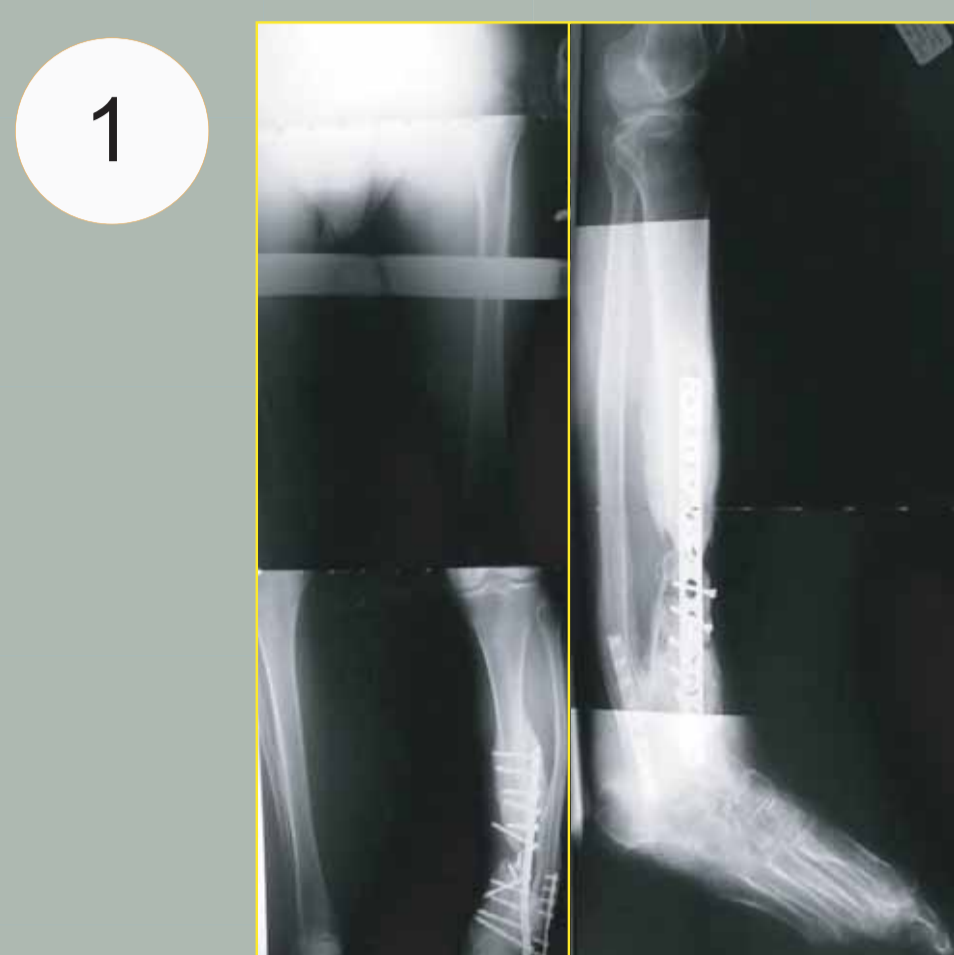

Three-year follow-up; Still ambulatory on stable leg. No additional surgery was necessary.

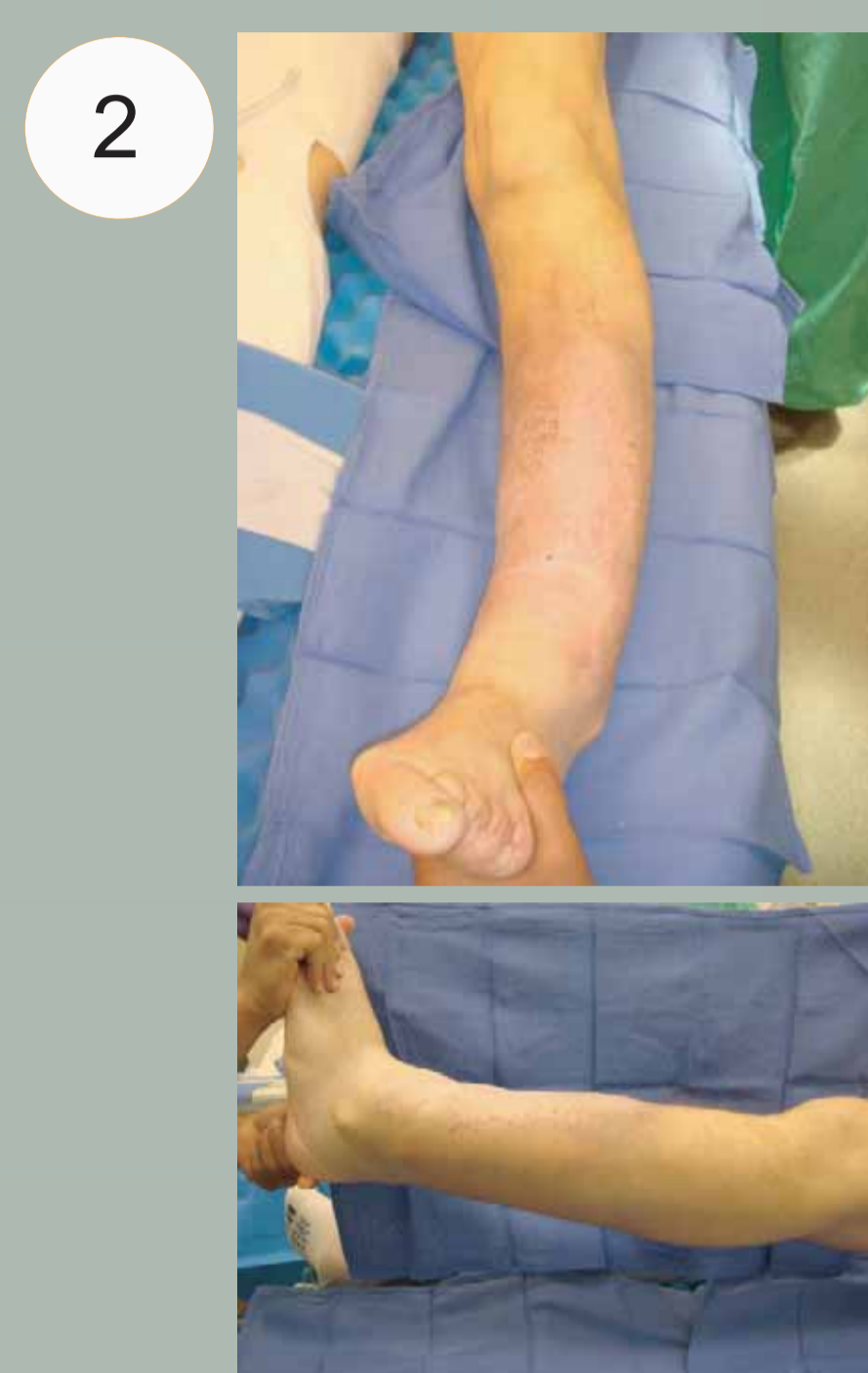Trans-Achilles approach healed well and avoided anterior soft envelope.

Cases and Conclusion

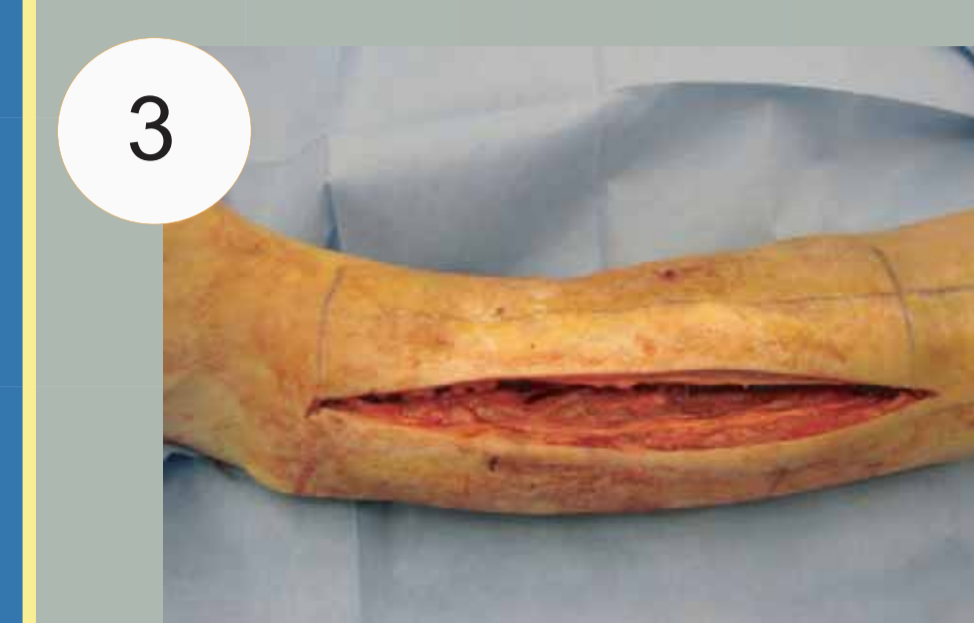Case 3



1 Preoperative radiographs of a 54-year-old male who has been diagnosed with schizophrenia. He had a land mine accident during the Vietnam war and now has a left distal tibial infected nonunion with a 6-cm defect. The patient underwent internal fixation in 2005 and developed infection. Three subsequent surgical procedures failed.

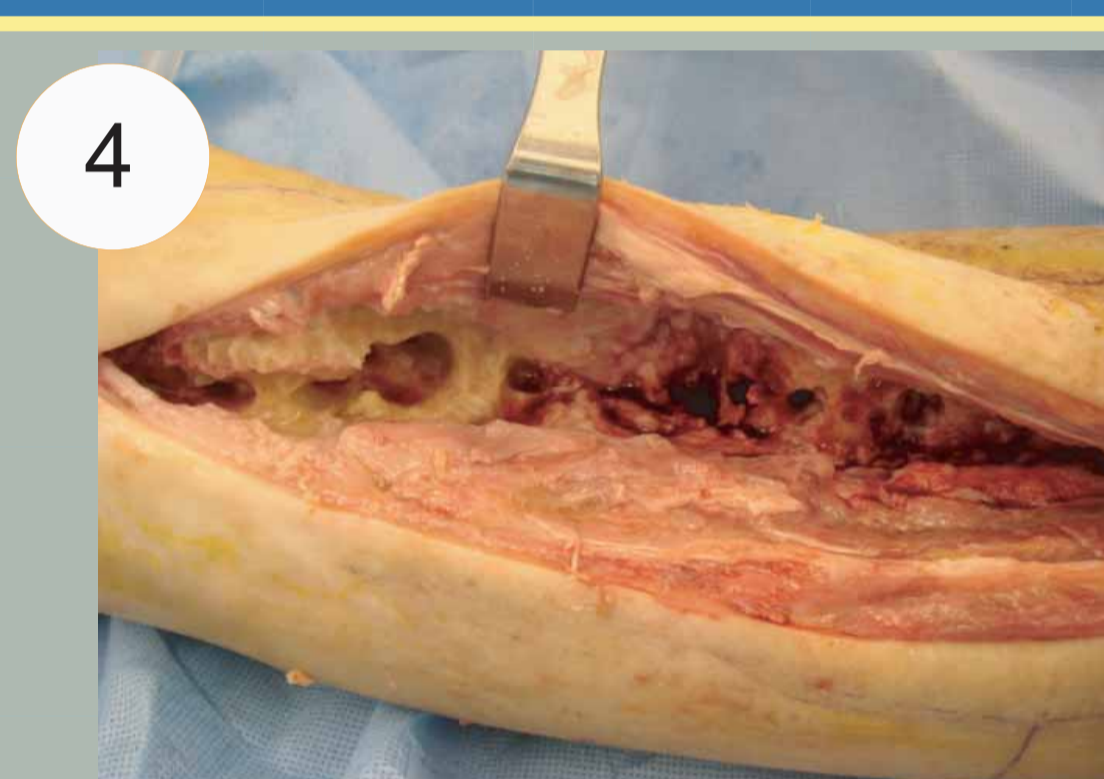

2 Preoperative photos.

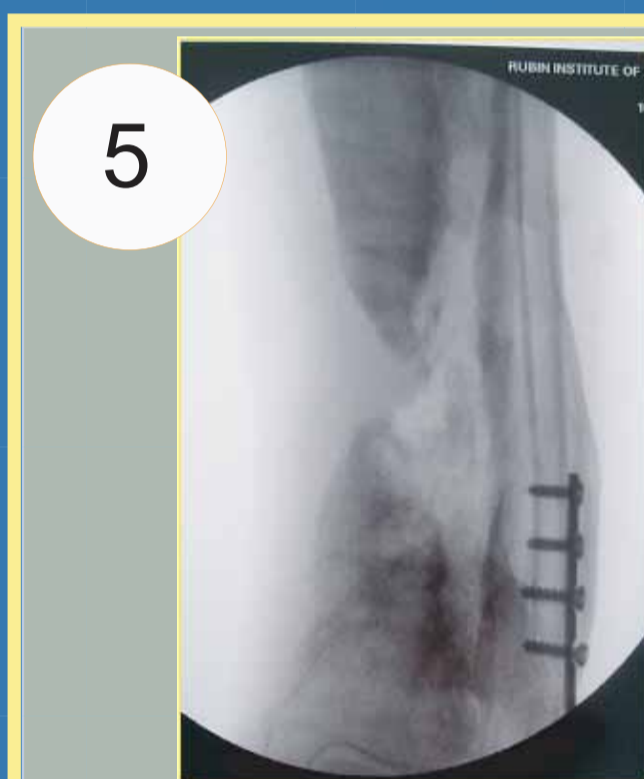

Surgical treatment included:

- Removal of hardware/osteomyelitis
- Débridement
- Fibular osteotomy
- Insertion of custom antibiotic-coated hindfoot fusion rod



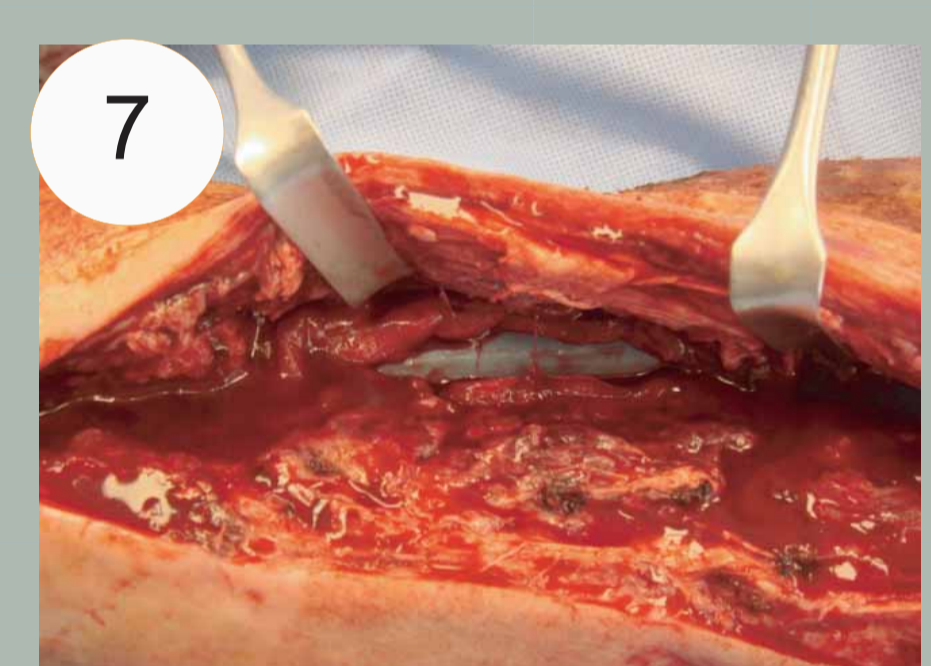
4 Intraoperative photo.



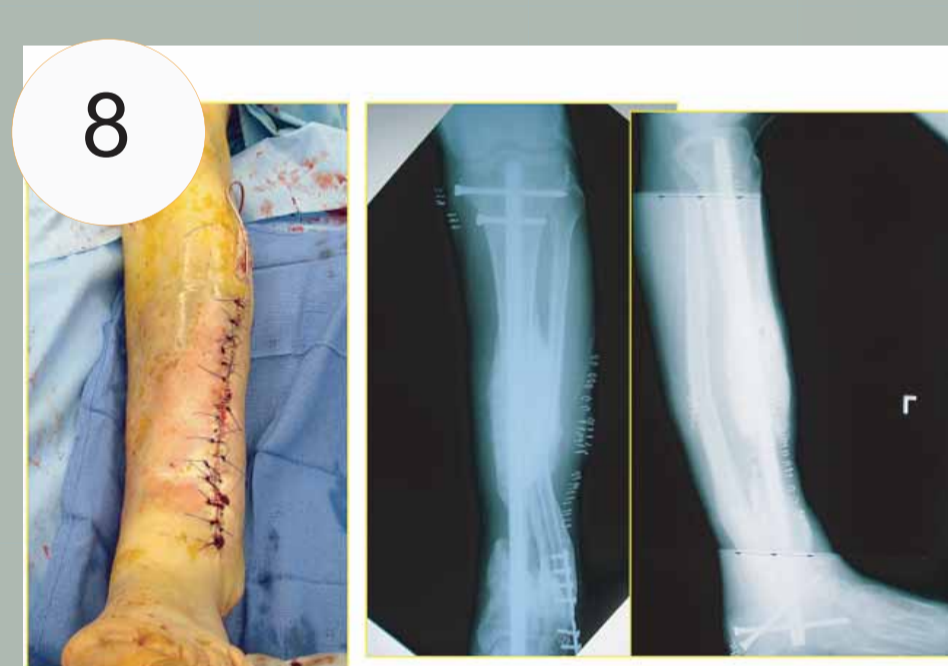5 Fluoroscopic view after resection.



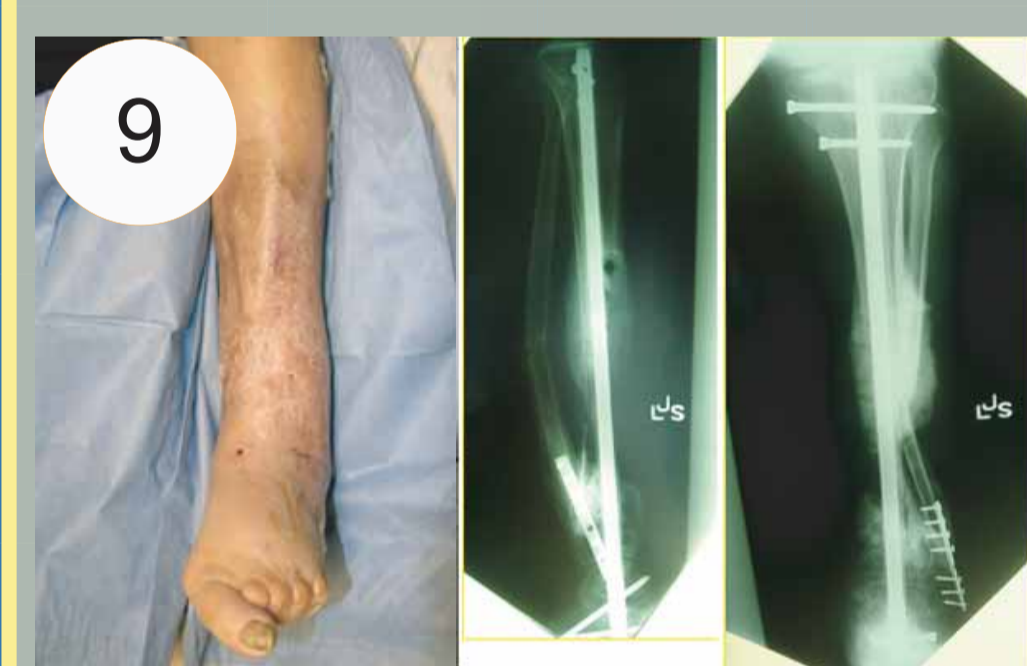6 Antibiotic-coated intramedullary rod.



7 Intraoperative photo after rod insertion.



8 Photo and radiographs obtained 2 weeks postoperatively.



9 Clinical photo and radiographs obtained 7 months postoperatively.

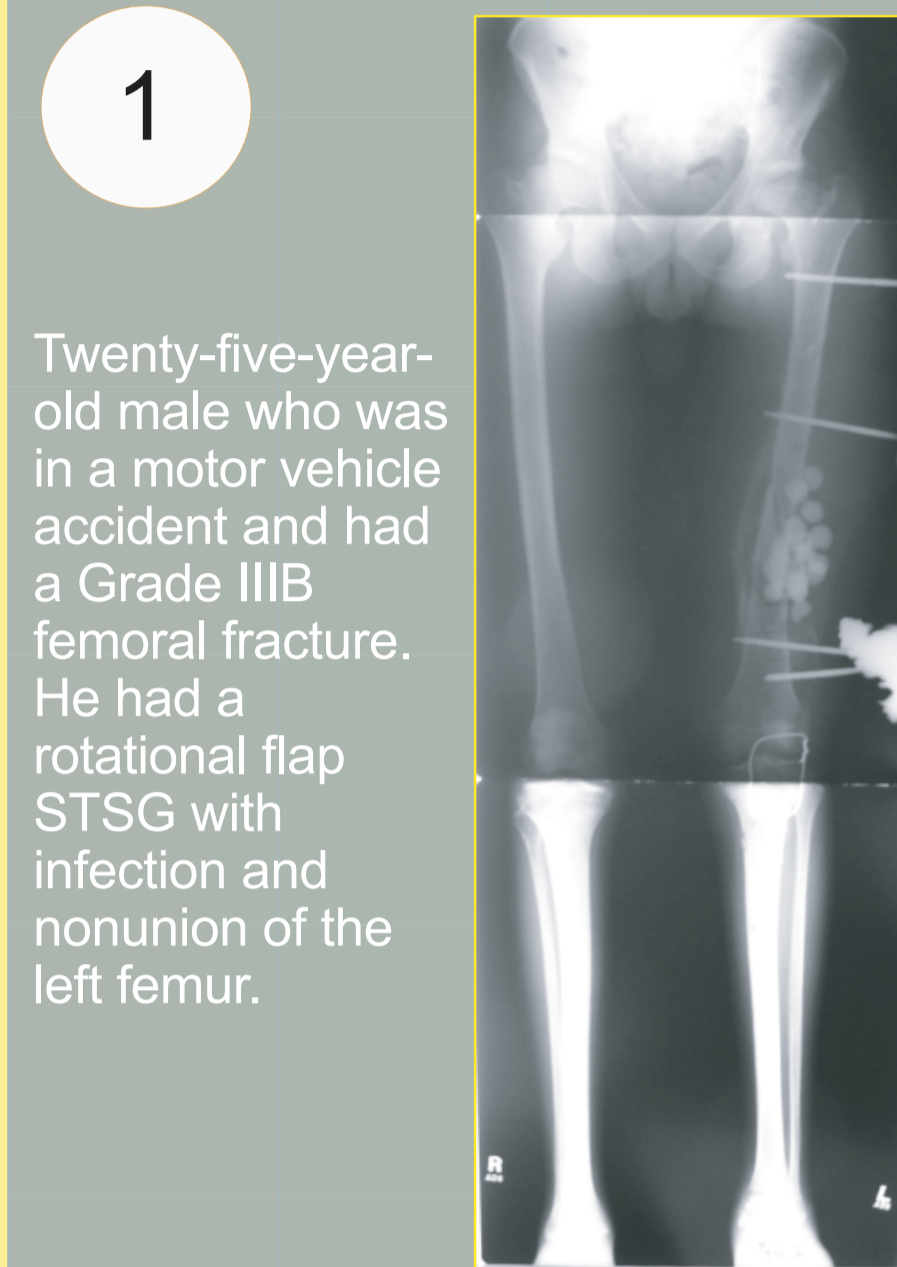
Conclusion

Both methods for creating the antibiotic-coated intramedullary rod are effective; however, the silicone tubing method at present has better reliability in the coating, has fewer complications with insertion, and takes less intraoperative time to create. The silicone tubing method is our current method of choice to create an antibiotic-coated intramedullary rod.

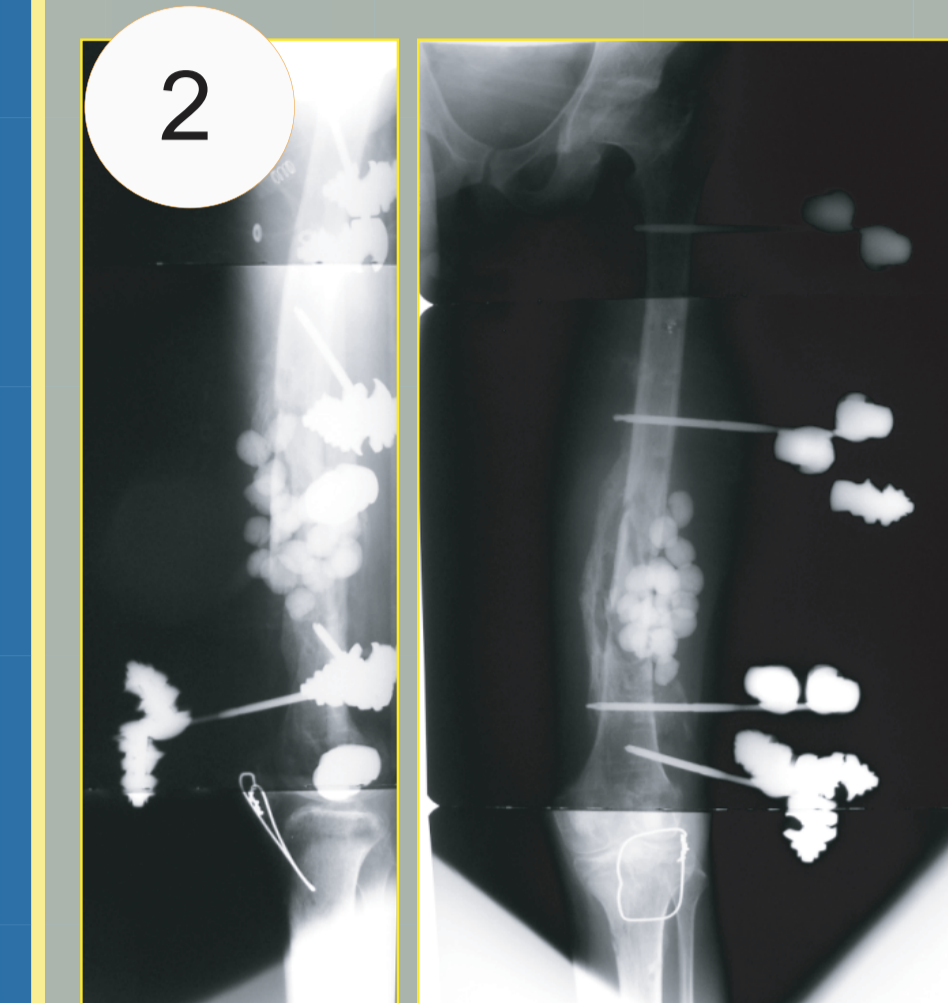
Overall, the antibiotic-coated intramedullary rod is extremely effective when treating infected nonunion and segmental bone defects. These cases would normally require long periods of external fixation and often bone transport. Our method has a 26% risk of an additional procedure for infection or nonunion. This is an acceptable risk given the difficult nature of the initial problem and a comparatively low risk when compared with the complications and additional surgical procedures reported in the Ilizarov literature.⁷

The only disadvantage with this method appears to be with rod removal. The arthroplasty cement removal instruments have been very effective in dealing with this problem. Additional research is being conducted to improve the cement bonding interface, and techniques are being developed to remove cement when it debonds during rod removal.

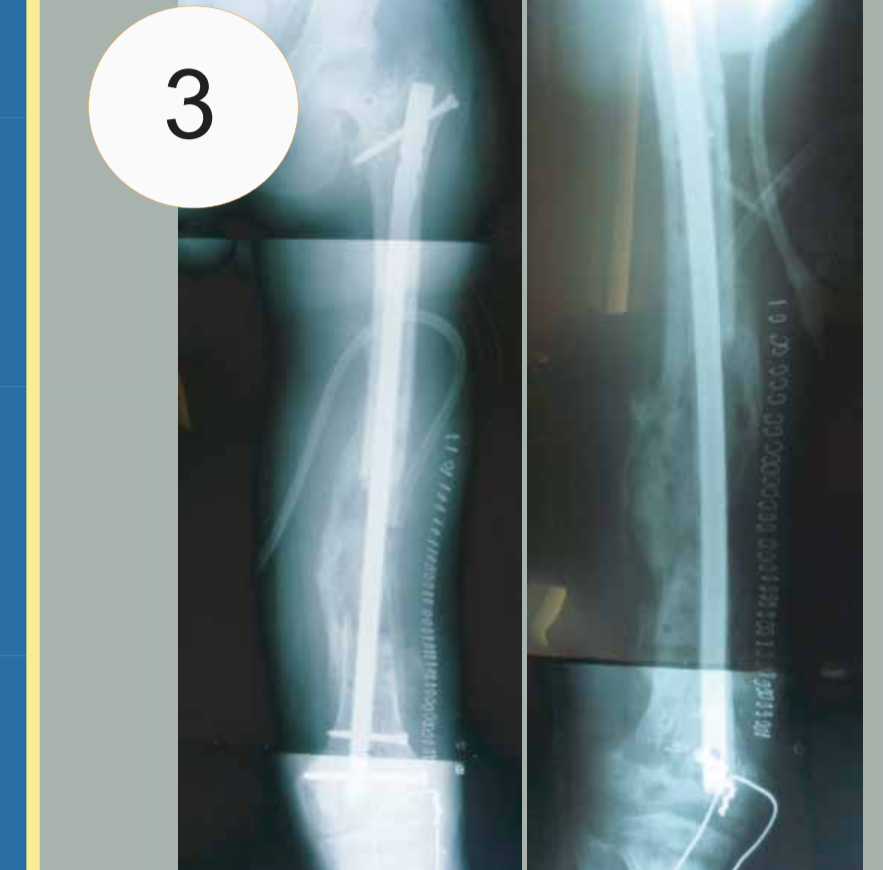Case 4



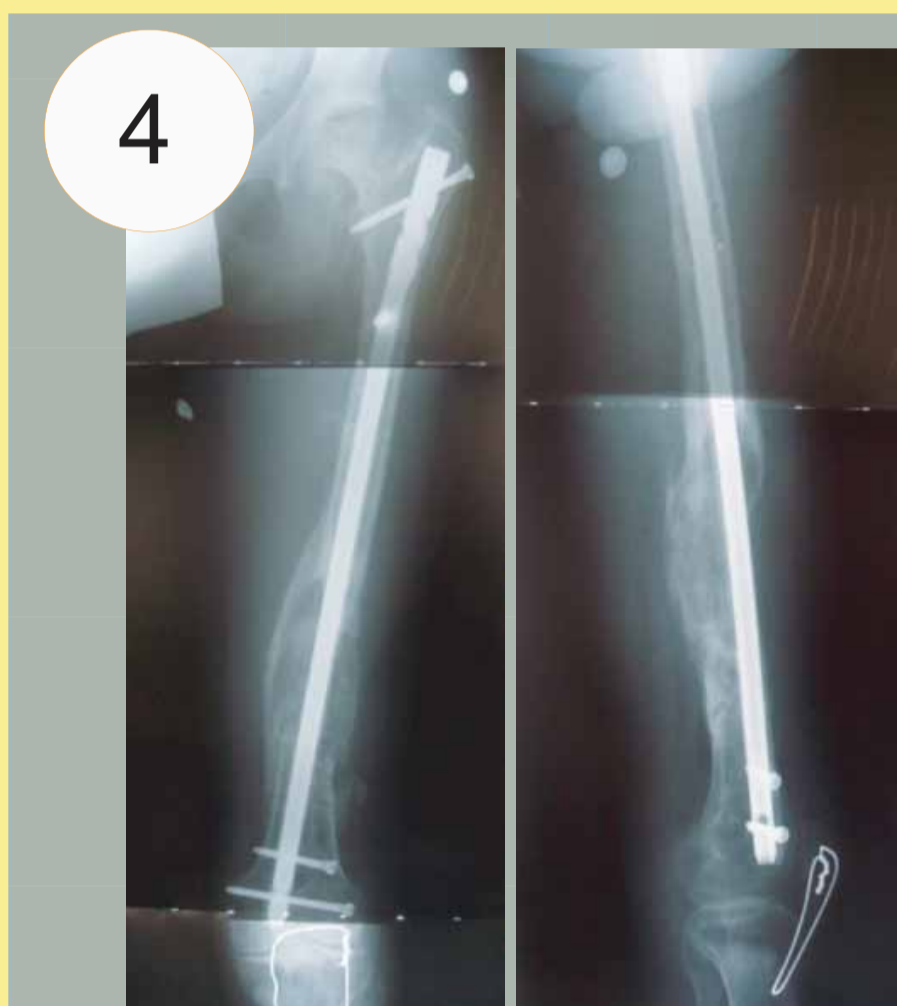1 Twenty-five-year-old male who was in a motor vehicle accident and had a Grade IIIB femoral fracture. He had a rotational flap STSG with infection and nonunion of the left femur.



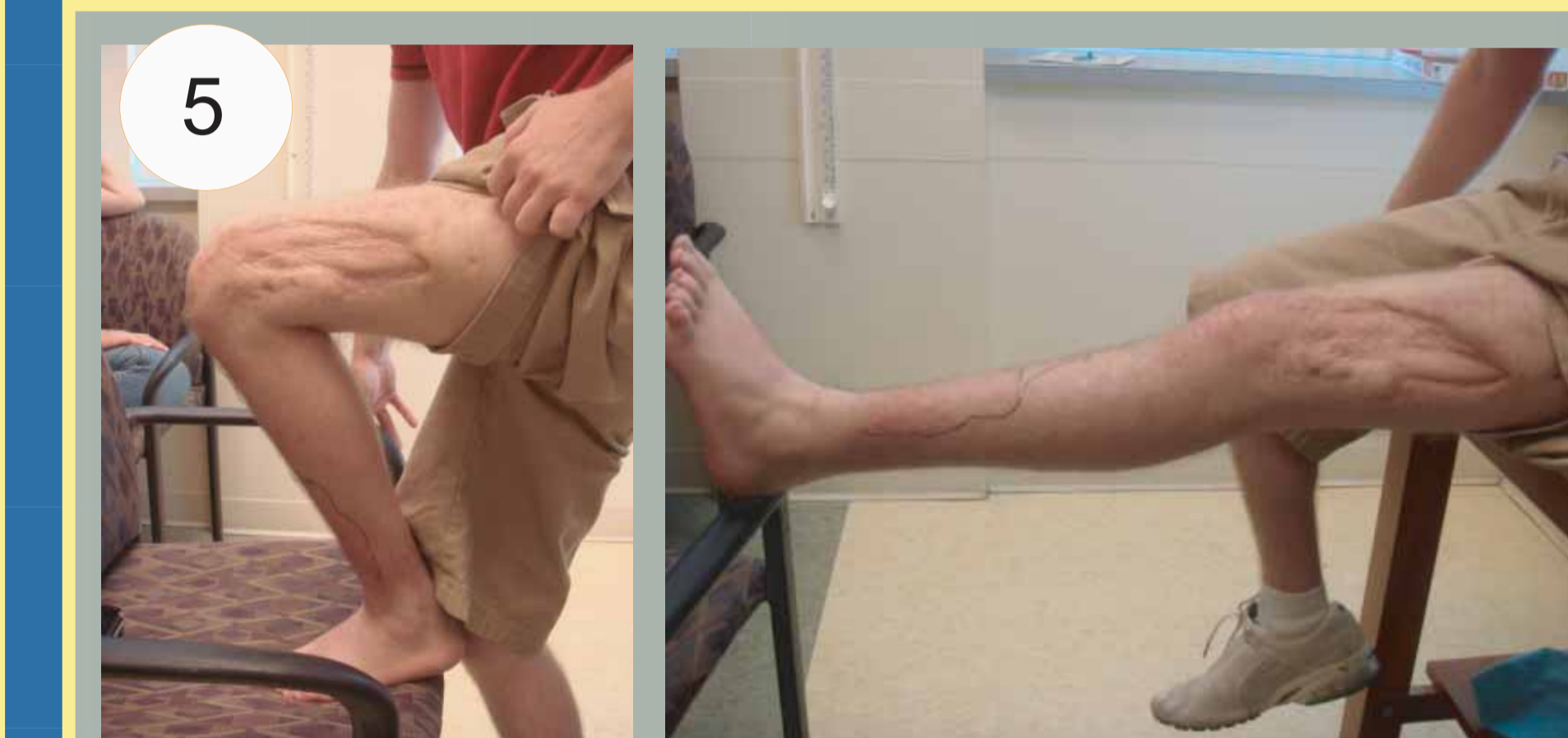2 Preoperative radiographs.



3 At the time of surgery, the medial bridge had healed but suspicious tissue/bone was noted. Before the surgical site was opened, the RIA was used to harvest bone graft. An antibiotic-coated rod was inserted, and antibiotics and BMP2 were added to the bone graft.




4 Postoperative radiographs.



5 Clinical photos obtained 8 months postoperatively.



6 One-year postoperative photos. Infection eradicated and bone healed.



Snowboarding

References

1. Patzakis MJ, Zalavras CG. Chronic posttraumatic osteomyelitis and infected nonunion of the tibia: current management concepts. *J Am Acad Orthop Surg.* 2005;13:417-427.
2. Beals RK, Bryant RE. The treatment of chronic open osteomyelitis of the tibia in adults. *Clin Orthop Relat Res.* 2005;433:212-217.
3. Zalavras CG, Patzakis MJ, Holtom P. Local antibiotic therapy in the treatment of open fractures and osteomyelitis. *Clin Orthop Relat Res.* 2004;427:86-93.
4. Henry SL, Ostermann PA, Seligson D. The prophylactic use of antibiotic impregnated beads in open fractures. *J Trauma.* 1990;30:1231-1238.
5. Thonse R, Conway J. Antibiotic cement-coated interlocking nail for the treatment of infected nonunions and segmental bone defects. *J Orthop Trauma.* 2007;21:258-68.
6. Cierny III G, Mader JT, Penninck JJ. A clinical staging system for adult osteomyelitis. *Contemp Orthop.* 1985;10:17-37.
7. Paley D. Problems, obstacles, and complications of limb lengthening by the Ilizarov technique. *Clin Orthop Relat Res.* 1990;250:81-104.